

# Cauda Equina Lymphoma: A Case Report Including Postmortem Examination

Aditya Mandawat, BS<sup>1</sup>  
M. Chadi Alraies, MD<sup>2</sup>  
Kennon Miller, MD<sup>3</sup>  
Sarah Ondrejka, MD<sup>3</sup>  
Stephen Smith, MD<sup>4</sup>

<sup>1</sup>*School of Medicine, Case Western Reserve University;* <sup>2</sup>*Departments of Medicine,* <sup>3</sup>*Anatomic and Clinical Pathology,* and <sup>4</sup>*Hematologic Oncologic and Blood Disorders; Cleveland Clinic Foundation, Cleveland, Ohio*

## Introduction

While primary central nervous system (CNS) lymphomas are rare, aggressive B-cell lymphomas may secondarily involve the CNS in up to 25% of patients with risk factors, particularly multiple extranodal sites of disease.<sup>1,2</sup> B-cell lymphomas very rarely present solely with lumbosacral neurologic signs consistent with cauda equina syndrome. Detection of lymphoma with CNS involvement can be difficult, in spite of advances in cerebrospinal fluid (CSF) analysis and imaging techniques. Herein, we describe a case of fatal large B-cell lymphoma presenting with cauda equina syndrome, without discernible nodal disease but with diffuse extranodal involvement at autopsy. We review radiographic and pathologic features of cauda equina lymphomas in light of 19 cases reported in the last 2 decades.<sup>3-21</sup>

## Case Presentation

A previously healthy 59-year-old man developed low back pain, symptoms of lumbar radiculopathy, and peroneal numbness following a cross-country drive. Contrast-enhanced magnetic resonance imaging (MRI) showed only mild lumbar spinal stenosis; electromyograms and nerve conduction studies were also unremarkable. Over 3 months, his symptoms progressed to paraplegia and urinary and fecal incontinence. Repeat contrast-enhanced MRI showed no interval change, and computed tomography (CT) of the chest, abdomen, and pelvis—and laboratory studies—were unremarkable.

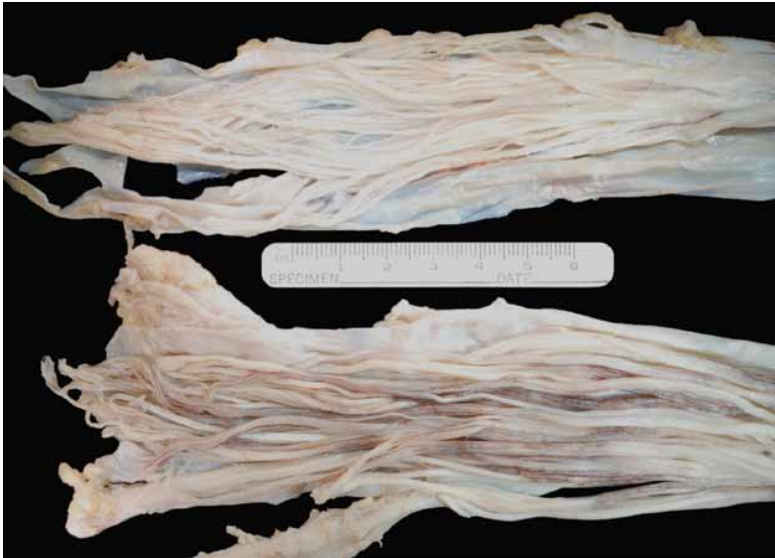At an academic center, laboratory evaluation found an elevated sedimentation rate and antinuclear antibody

(titer 1:2500), and positive anticardiolipin antibody (IgM). Sural nerve biopsy was negative for vasculitis, and muscle biopsy showed denervation atrophy. Bone marrow biopsy, including flow cytometry, was negative. A diagnosis of antiphospholipid syndrome with myelitis was made, and therapy with hydroxychloroquine and high-dose steroids was started, with significant improvement.

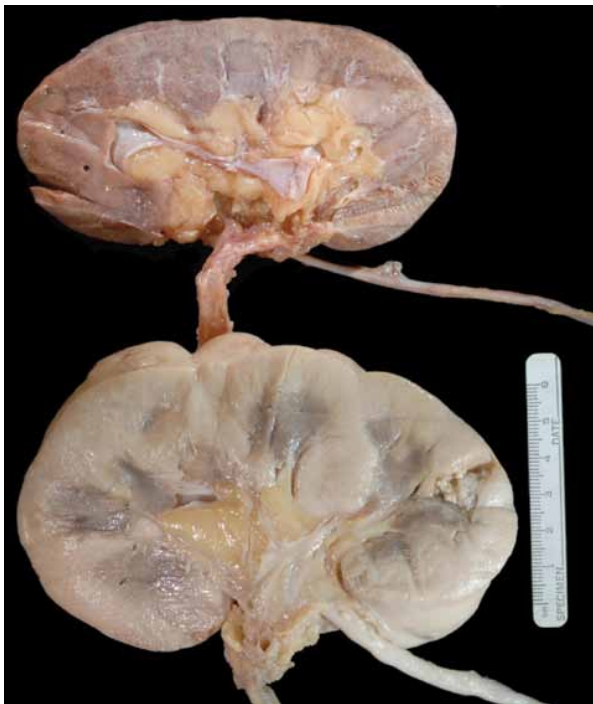However, upon tapering of the steroid dose, lower extremity weakness recurred. Steroids were resumed and cyclophosphamide was added. One week later, the patient developed renal failure (serum creatinine 3.4 mg/dL) attributed to hyperglycemia with volume depletion related to steroids. The patient was transferred to our hospital for further management.

On admission, the patient was alert and oriented; no adenopathy was present on exam. Extremities were edematous. Motor strength and sensation to pinprick were decreased in the lower extremities. Lumbar puncture showed mildly elevated protein content, and CSF analysis showed rare atypical lymphocytes, though cytopathology review noted no malignancy. Flow cytometry was negative for a monoclonal B-cell population. Due to renal failure (creatinine clearance 20 cc/min), a noncontrast MRI of the brain and spine was performed; this showed findings consistent with arachnoiditis at L3–L4. CT imaging of the chest, abdomen, and pelvis was normal. Lactate dehydrogenase was mildly elevated (300 U/L; normal  $\leq 220$  U/L). Renal ultrasound showed kidney sizes of 12.9 and 13.0 cm. Steroids were decreased, and the patient clinically worsened, with diffuse loss of muscle strength. Due to worsening renal failure, the patient was started on hemodialysis; renal biopsy was not performed. A second bone marrow biopsy was undertaken. Soon after, the patient developed hypotension and was transferred to the intensive care unit; this was followed by respiratory failure, requiring intubation, and full cardiopulmonary arrest. Resuscitation efforts were unsuccessful. Bone marrow biopsy reported during this episode showed involvement

Address correspondence to:  
Stephen D. Smith, MD, Department of Hematologic Oncology and Blood Disorders, Cleveland Clinic Foundation, R35, 9500 Euclid Avenue, Cleveland, OH 44195; Phone: 216-444-8258; Fax: 312-503-2555; E-mail: smiths11@ccf.org.



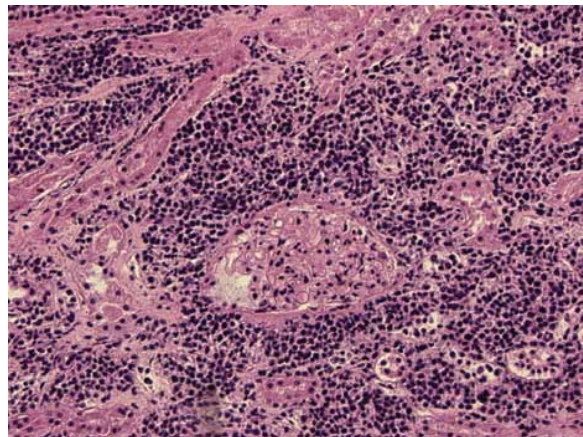
**Figure 1.** Normal cauda equina (top) and postmortem sample showing thickened nerve roots and cauda equina with patchy vascular prominence.



**Figure 2.** Normal kidney (top) and postmortem specimen with diffuse pallor and enlargement. The kidney weighed 388 g and measured  $13.6 \times 8.1 \times 6.2$  cm.

by a CD20-positive large B-cell lymphoma representing less than 10% of marrow cellularity.

A postmortem exam was performed, revealing multiple segmental artery thrombi in both lungs. The cauda equina and nerve roots were thickened, and histologic examination showed an infiltrate of large, CD20-



**Figure 3.** Microscopic hematoxylin and eosin kidney section shows a diffuse infiltrate of large atypical lymphocytes expanding the interstitium. Immunohistochemical stains for CD20 and bcl-6 were positive.

positive lymphocytes (Figure 1, normal cauda equina shown for comparison). The kidneys were pale in color and enlarged, with a combined weight of 784 grams (Figure 2, normal kidney shown for comparison). Both kidneys were involved by a diffuse lymphomatous infiltrate on microscopic examination (Figure 3). The lymphoma was also found to grossly involve the stomach, liver, pancreas, spleen, right coronary artery peridipose tissue, and adrenals. Microscopic involvement of the myocardium was also found on routine examination. Further pathology showed that the neoplastic B cells were CD20-positive, CD10-negative, Bcl6-positive, and MUM-1-negative, a

**Table 1.** Cauda Equina Lymphomas: Radiologic, Pathologic, and Clinical Features

Author	Year	Age/Sex	Dx	Radiologic Findings	LP/Pathologic Findings	Treatment	Outcome
Ogilvie <sup>3</sup>	2010	58/M	NHL	Intraspinal mass, T11–L4	No LP; mass Bx: DLBCL, (+) CD20, BCL6, BCL2, MUM1	Laminectomy, R + chemo	Improved
Piyatanont <sup>4</sup>	2010	77/M	IVL	MRI: cauda equina enhancement	CSF: pleocytosis, high protein, low glucose, cytology (-). Skin Bx: IVL	Not discussed	Not discussed
Tahiri <sup>5</sup>	2009	58/F	NHL	MRI: abnormal signal in lumbar vertebrae	No LP. Surgical Bx: DLBCL, CD20 (-)	Laminectomy, chemo	Improved
Ingber <sup>6</sup>	2008	44/M	HL	MRI: cauda equina enhancement	CSF: high protein, mild pleocytosis, cytology (-). Inguinal node Bx: NLPHL	Steroids, IVIg then chemo	Improved
Tajima <sup>7</sup>	2007	67/F	NHL	MRI: cauda equina edema, enhancement, mass	CSF: high protein, pleocytosis, high IgG. Mass Bx: DLBCL	RT+ chemo	Improved
Aznar <sup>8</sup>	2007	47/M	IVL	MRI: focal, fusiform thickening of the conus medullaris	CSF: high protein. Bx of conus medullaris (-); dx on autopsy	None	Died
Santoro <sup>9</sup>	2006	45/F	NHL	Total body sestamibi-Tc99 scan: osteoclastic lesions	CSF: high protein, IgG; Bx: NHL with plasmacytic differentiation	Chemo, steroids	Improved
Ohno <sup>10</sup>	2006	46/F	IVL	MRI of the spine: normal Gallium scan: normal CT abdomen: enlarged kidneys, splenomegaly	CSF: high protein, pleocytosis. Renal Bx: IVL, CD5+, CD10-, CD20+	R + chemo	Died
Kumar <sup>11</sup>	2005	60/M	NHL	MRI: cauda equina thickening, enhancement	CSF: high protein, normal glucose, cytology (-). BM Bx: LPL	IVIg then R	Improved
Davis <sup>12</sup>	2003	86/M	IVL	CT spine and myelogram: spinal stenosis	No LP; muscle biopsy: IVL, CD20+, CD3-, CD5-	Chemo, steroids, then R	Improved
Zagami <sup>13</sup>	2003	71/F	NHL	MRI: cauda equina thickening, enhancement Gallium scan: vertebral, lymph node, tibial uptake	CSF: abnormal lymphoid cells. Laminectomy: DLBCL	Chemo, then laminectomy	Died
Ampil <sup>14</sup>	2001	21/M	NHL	Myelogram: extradural defect L3–L5 CT spine: paraspinal mass	LP not noted. Mass Bx: mixed large cell cleaved/small cell noncleaved lymphoma	Laminectomy, RT + chemo	Improved
Viali <sup>15</sup>	2000	53/M	IVL	MRI: abnormal signal in the conus; CT negative	CSF: high protein; dx on autopsy	Steroids, IVIg	Died

(Table continues on following page)

germinal center phenotype large B-cell lymphoma based on criteria of Hans and colleagues.<sup>22</sup>

## Discussion and Literature Review

Diffuse large B-cell lymphoma may present primarily with extranodal involvement in up to one-third of

patients, with the gastrointestinal tract most frequently involved.<sup>23</sup> However, presentation with cauda equina lymphoma is rare. We identified 19 English-language case reports of B-cell lymphomas presenting with cauda equina syndrome published since 1990; they are summarized in Table 1. Histologically, most cases are large B-cell non-Hodgkin lymphomas, though 2 reported cases

**Table 1.** (Continued) Cauda Equina Lymphomas: Radiologic, Pathologic, and Clinical Features

Author	Year	Age/Sex	Dx	Radiologic Findings	LP/Pathologic Findings	Treatment	Outcome
Nakahara <sup>16</sup>	1999	63/M	IVL	Spinal CT, myelogram, MRI, and gallium scan negative	CSF: high protein, pleocytosis. Muscle Bx: IVL, CD20+CD3-	Steroids then chemo	Improved
Giobbia <sup>17</sup>	1999	30/F	NHL	MRI: cauda equina enhancement	CSF: high protein, low glucose, and pleocytosis, cytology (+) DLBCL	Chemo, steroids, then RT	Improved
Batchelor <sup>18</sup>	1997	67/F	NHL	MRI: destructive lesion L2/L3, enveloping cauda equina and nerve roots	CSF: malignant lymphoma, large-cell	Withheld per family wishes	Died
Toprak <sup>19</sup>	1997	20/M	HL	MRI: sacroiliac lesions, epidural mass	LP not noted; NSCHL on bone marrow and lymph node biopsy	Chemo	Improved
Fong <sup>20</sup>	1997	62/M	NHL	CT spine: negative MRI brain/spine: negative	CSF: high protein, low glucose. BM biopsy (-). Liver Bx: high-grade B NHL	Not discussed	Not discussed
Hopkins <sup>21</sup>	1993	32/M	NHL	MRI: epidural mass T12-L4/5	CSF: high protein. Mass Bx: NHL, immunoblastic features	Laminectomy	Not discussed

BM=bone marrow; Bx=biopsy; CSF=cerebrospinal fluid; CT=computed tomography; DLBCL=diffuse large B-cell lymphoma; Dx=diagnosis; HL=Hodgkin lymphoma; IVL=intravascular lymphoma; LP=lumbar puncture; LPL=lymphoplasmacytic lymphoma; MRI=magnetic resonance imaging; NHL=Non-Hodgkin lymphoma; NPLHL=nodular lymphocyte-predominant Hodgkin lymphoma; NSCHL=nodular sclerosing classical Hodgkin lymphoma; R=rituximab; RT=radiotherapy.

of Hodgkin lymphoma, and a large proportion of cases of intravascular lymphoma (IVL, 6/19) were identified. Two of the cases of IVL were diagnosed on autopsy; others were diagnosed by muscle biopsy (2 cases), skin biopsy (1 case), or renal biopsy (1 case). In our case, large B-cell lymphoma with a germinal center phenotype was diagnosed on a second bone marrow biopsy immediately prior to expiration from pulmonary embolism and during postmortem examination. BCL-6 positivity in this case is consistent with an extensive prior report of extranodal lymphomas.<sup>23</sup>

Radiographic findings in cauda equina lymphoma may be subtle. The MRI finding of contrast enhancement (+/- thickening) of the cauda equina was the only abnormality in 6 of 9 reported cases. Other cases presented with mass lesions, bony disease, or distant adenopathy/organomegaly. Patients such as ours with a glomerular filtration rate of less than 30 mL/min/1.73 m<sup>2</sup> constitute a particularly high-risk group for developing nephrogenic systemic fibrosis after gadolinium contrast for MRI, characterized by fibrosis of skeletal muscle, bone, lungs, pleura, and myocardium.<sup>24,25</sup> Contrast nephropathy due to iodinated CT contrast may result in irreversible renal injury, necessitating lifelong dialysis.<sup>26,27</sup> Furthermore, even when indicated in patients with normal renal func-

tion, contrast-enhanced MRI and CT may not detect lesions until late in the disease course. Clinical manifestations may precede MRI enhancement, particularly in lymphomas arising as primary tumors of the spinal cord, but they are often nonspecific.<sup>28</sup> Contrast-enhanced MRI is also poor at detecting leptomeningeal dissemination, with enhancement detected in only 4% of patients versus 16.1% by cytology in a recent study.<sup>29</sup> Use of positron-emission tomography (PET) has not been reported, though in absence of clear MRI or CT, abnormalities amenable to biopsy may have little potential to change management.

Finally, CSF analysis fails to provide a specific diagnosis in most cases. Elevated protein (12/19 reported cases) and pleocytosis (5/19) are common but nonspecific findings in published cases of cauda equina lymphoma. CSF cytology was positive in only 3 cases. Frequent false-negative results of CSF cytology in CNS lymphomas may be related to the paucity of tumor cells, which may in part be overcome by obtaining large CSF sample volumes and repeated sampling. Some data suggest steroids may not affect the chances of obtaining positive cytomorphology.<sup>29</sup> Patients with suspected meningeal involvement by lymphoma should undergo evaluation by flow cytometry. In a study of 51 newly diagnosed aggressive B-cell

lymphomas at risk for CNS involvement, all 11 cases of occult CSF involvement were detected by flow cytometry but only 1 by cytology ( $P=.002$ ).<sup>30</sup> Immunoglobulin heavy chain polymerase chain reaction (PCR) analysis is often discordant with CSF cytology (Kappa=0.18) and MRI (Kappa=0.19), and may be unreliable in patients taking corticosteroids.<sup>29,31</sup> This may, nevertheless, be a useful test early in the diagnostic process.<sup>32</sup> At present, a full diagnostic evaluation of CSF should include cytology and flow cytometry, and heavy-chain PCR in centers with the available technology and expertise.

In this case, diagnostic difficulties were posed by comorbidities (renal failure, discovered at the time of autopsy to be attributable to renal infiltration, precluding IV contrast), prior immunosuppressive therapy (which may have modulated his imaging findings and disease course), and the limitations of CSF analysis despite use of flow cytometry. A renal biopsy in this case may have yielded a more timely diagnosis, as a matter of speculation. Clinical improvement was reported in 11 patients with cauda equina lymphoma with use of chemotherapy and rituximab (Rituxan, Genentech) once diagnosis was ascertained; this suggested that therapy is not futile, though palliation should remain the primary goal. Extranodal lymphoma should be strongly considered in patients presenting with an otherwise cryptic cauda equina syndrome, and biopsy of compromised organs or those with signs of infiltration should accompany complete CSF analysis (including flow cytometry) and bone marrow biopsy. This approach may maximize the chance of obtaining a timely diagnosis to allow initiation of anti-neoplastic therapy, which may provide palliation or even prolongation of survival.

## References

- van Besien K, Ha CS, Murphy S, et al. Risk factors, treatment, and outcome of central nervous system recurrence in adults with intermediate-grade and immunoblastic lymphoma. *Blood*. 1998;91:1178-1184.
- Boehme V, Zeynalova S, Kloess M, et al. Incidence and risk factors of central nervous system recurrence in aggressive lymphoma—a survey of 1693 patients treated in protocols of the German High-Grade Non-Hodgkin's Lymphoma Study Group (DSHNHL). *Ann Oncol*. 2007;18:149-157.
- Ogilvie C, Lund K, McKay P, Leach M. Extranodal or primary CNS DLBC lymphoma? *EJC Supplements*. 2010;8:19.
- Piyatanont K, Bamrungrak K, Watcharangnan S, et al. Intravascular B-cell lymphoma presenting with cauda equina syndrome: the role of skin biopsy. *Eur J Dermatol*. 2010;20:821-822.
- Tahiri L, Benbouazza K, Amine B, Allali F, El Mesbahi O, Hajjaj-Hassouni N. Primary non-Hodgkin's lymphoma presenting as radicular syndrome: report of two cases. *Rheumatol Int*. 2009;30:113-117.
- Ingber S, Buckstein R. Paraneoplastic lumbosacral axonal polyradiculopathy preceding the diagnosis of nodular lymphocyte predominant Hodgkin lymphoma: a case report. *Leuk Lymphoma*. 2008;49:2009-2011.
- Tajima Y, Sudo K, Matumoto A. Malignant lymphoma originating in the cauda equina mimicking the inflammatory polyradiculoneuropathy. *Intern Med*. 2007;46:1029-1032.
- Aznar AO, Montero MA, Rovira R, Vidal FR. Intravascular large B-cell lymphoma presenting with neurological syndromes: clinicopathologic study. *Clin Neuropathol*. 2007;26:180-186.
- Santoro L, Manganelli F, Bruno R, Nolano M, Provitera V, Barbieri F. Sural nerve and epidermal vascular abnormalities in a case of POEMS syndrome. *Euro J Neurol*. 2006;13:99-102.
- Ohno T, Sakamoto T, Mizumoto C, et al. Leukemic and meningeal relapse of CD5(+) intravascular large B-cell lymphoma with down-modulation of CD20 after rituximab therapy. *Int J Hematol*. 2006;84:74-78.
- Kumar N, Dyck PJB. Hypertrophy of the nerve roots of the cauda equina as a paraneoplastic manifestation of lymphoma. *Arch Neurol*. 2005;62:1776-1777.
- Davis TS. Intravascular lymphoma presenting with cauda equina syndrome: treated with CHOP and rituxan. *Leuk Lymphoma*. 2003;44:887-888.
- Zagami AS, Granot R. Non-Hodgkin's lymphoma involving the cauda equina and ocular cranial nerves: case reports and literature review. *J Clin Neurosci*. 2003;10:696-699.
- Ampil F, Polin R, Nanda A. Cauda equina compression by malignant lymphoma: long-term survival following multimodality therapy. *Leuk Lymphoma*. 2001;41:417-420.
- Viali S, Hutchinson DO, Hawkins TE, et al. Presentation of intravascular lymphomatosis as lumbosacral polyradiculopathy. *Muscle Nerve*. 2000;23:1295-1300.
- Nakahara T, Saito T, Muroi A, et al. Intravascular lymphomatosis presenting as an ascending cauda equina: conus medullaris syndrome: remission after biweekly CHOP therapy. *J Neurol Neurosurg Psychiatry*. 1999;67:403-406.
- Giobbia M, Carniato A, Scotton PG, Vaglia A, Marchiori GC. Primary EBV-associated cauda equina lymphoma. *J Neurol*. 1999;246:739-740.
- Batchelor TT, Louis DN. Case records of the Massachusetts General Hospital. Weekly clinicopathological exercises. Case 39-1997. A 67-year-old woman with the cauda equina syndrome. *N Engl J Med*. 1997;337:1829-1837.
- Toprak A, Kodalli N, Alpdogan TB, et al. Stage IV Hodgkin's disease presenting with spinal epidural involvement and cauda equina compression as the initial manifestation: case report. *Spinal Cord*. 1997;35:704-707.
- Fong GC, Fong KY. Paraneoplastic cauda equina syndrome secondary to B-cell lymphoma. *Clinic Neurol Neurosurg*. 1997;99:71-72.
- Hopkins TJ, Raducan V, Sioutos N, White A. Lumbar lymphoma presenting as psoas abscess epidural mass with acute cauda-equina syndrome. *Spine*. 1993;18:774-778.
- Hans CP, Weisenburger DD, Greiner TC, et al. Confirmation of the molecular classification of diffuse large B-cell lymphoma by immunohistochemistry using a tissue microarray. *Blood*. 2004;103:275-282.
- López-Guillermo A, Colomo L, Jiménez M, et al. Diffuse large B-cell lymphoma: clinical and biological characterization and outcome according to the nodal or extranodal primary origin. *J Clin Oncol*. 2005;23:2797-2804.
- Grobner T, Prischl FC. Patient characteristics and risk factors for nephrogenic systemic fibrosis following gadolinium exposure. *Semin Dial*. 2008;21:135-139.
- Broome DR, Girguis MS, Baron PW, Cottrell AC, Kjellin I, Kirk GA. Gadodiamide-associated nephrogenic systemic fibrosis: why radiologists should be concerned. *Am J Roentgenol*. 2007;188:586-592.
- Finn WF. The clinical and renal consequences of contrast-induced nephropathy. *Nephrol Dial Transplant*. 2006;21:i2-10.
- Rosenkranz AR, Grobner T, Mayer GJ. Conventional or gadolinium containing contrast media: the choice between acute renal failure or nephrogenic systemic fibrosis? *Wien Klin Wochenschr*. 2007;119:271-275.
- Herrlinger U, Weller M, Kuker W. Primary CNS lymphoma in the spinal cord: clinical manifestations may precede MRI detectability. *Neuroradiology*. 2002;44:239-244.
- Fischer L, Martus P, Weller M, et al. Meningeal dissemination in primary CNS lymphoma: prospective evaluation of 282 patients. *Neurology*. 2008;71:1102-1108.
- Hegde U, Filie A, Little RF, et al. High incidence of occult leptomeningeal disease detected by flow cytometry in newly diagnosed aggressive B-cell lymphomas at risk for central nervous system involvement: the role of flow cytometry versus cytology. *Blood*. 2005;105:496-502.
- Gleissner B, Siehl J, Korfel A, Reinhardt R, Thiel E. CSF evaluation in primary CNS lymphoma patients by PCR of the CDR III IgH genes. *Neurology*. 2002;58:390-396.
- Abrey LE, Batchelor TT, Ferreri AJ, et al. Report of an international workshop to standardize baseline evaluation and response criteria for primary CNS lymphoma. *J Clin Oncol*. 2005;23:5034-5043.

# Review

## Lymphomatous Meningitis as a Presentation of Non-Hodgkin Lymphoma

Marc C. Chamberlain, MD

*Department of Neurology and Neurosurgery  
University of Washington/Fred Hutchinson Cancer Center  
Seattle, Washington*

The case report by Mandawat and colleagues<sup>1</sup> is instructive for several reasons. Firstly, and as illustrated in the case report, cancer, whether solid or hematologic, may rarely initially present with neurologic dysfunction.<sup>2-5</sup> The case under discussion was an unusual and uncommon neurologic disorder affecting the terminal spinal cord—the cauda equina. The cauda equina comprises spinal nerve roots within the lumbar cistern that exit the subarachnoid space and innervate lumbar and sacral dermatomes.<sup>6-8</sup> The syndrome manifests as asymmetric sensory and lower motor neuron dysfunction with late-appearing paraplegia and incontinence, as seen in the case presented. Recognizing that the cauda equina is anatomically within the subarachnoid compartment limits the differential diagnosis to 1 of 3 likely possibilities: an intradural extramedullary spinal cord tumor, an extradural spinal cord mass (tumor or abscess), or a primary meningeal process such as meningitis (neoplastic, infectious, or inflammatory not otherwise specified).<sup>6,7</sup> Consequently, the appropriate neurologic work-up for a cauda equina syndrome (CES) would include anatomic imaging of the region of interest (the lumbosacral spine) using magnetic resonance imaging with contrast and lumbar puncture to interrogate cerebrospinal fluid (CSF; to include an opening pressure, cell count, glucose, protein, cytology, and flow cytometry). In the instance that the initial work-up is negative, repeating the above mentioned studies would be appropriate and indicated. If a second work-up is negative, then consideration of ancillary central nervous system-directed testing such as fluorodeoxyglucose positron emission tomography (FDG-PET) is appropriate, as it can resolve

disease of nerve roots as seen in neurolymphomatosis. Anatomic causes of the CES, best determined by imaging, include epidural (extradural) metastatic or primary vertebral body tumor (giant cell tumor, chordoma), abscess, hematoma (ie, secondary to trauma and a vertebral body fracture), degenerative spine disease (lumbar stenosis or disc herniation), and intradural extramedullary tumor (ie, myxopapillary ependymoma, peripheral nerve sheath tumor or paraganglioglioma); congenital causes include a tethered filum (cord) or diastematomyelia. Meningitic syndromes giving rise to the CES may include neoplastic meningitis, infectious meningitis (mycobacterium, fungal, cytomegalovirus, herpes, human T-lymphotropic virus type I), or inflammatory causes not otherwise specified, such as intracranial CSF chemotherapy-related toxicity, sarcoidosis, or Sjogren's syndrome.

Of interest in the case under discussion is meningeal syndromes caused by neoplasms, particularly lymphomatous meningitis (LM).<sup>3-5</sup> LM, like other causes of neoplastic meningitis (leukemic and carcinomatous), is a disorder that affects the meninges (ie, arachnoid and pia-arachnoid) and the CSF compartment, and involves the entire neuraxis (spine, brain, and exiting nerves). Neoplastic meningitis in the majority of case series most often presents with spinal cord dysfunction (approximately 60%) and commonly a CES. LM may represent a primary CNS lymphoma, though a purely spinal cord and meningeal syndrome is quite rare (<5%). More commonly, LM is a manifestation of leptomeningeal metastasis from a systemic lymphoma and primarily, as in the case under discussion, from a diffuse large B-cell lymphoma. When LM is seen in the context of systemic lymphoma, discovery occurs overwhelmingly after diagnosis, during systemic treatment, and usually within 6 months of diagnosis while on treatment. It is recognized that there are patients with systemic lymphoma at high risk of LM; however, at present, there are no agreed upon criteria for performing upfront CNS staging that includes a lumbar puncture. CSF analysis for lymphoma is best determined by flow cytometry, a CSF volume-independent but laboratory-dependent test most useful for hematologic tumors metastatic to the leptomeninges. In rare instances, CSF cytology (a volume-dependent test requiring 10 mL or more of CSF) will be positive and flow cytometry will be negative. Nonetheless, there exists a fraction of patients with negative CSF and MRI that appears to have LM clinically, such as the case under discussion. A steroid-responsive disorder, at least with respect to neoplastic meningitis, is highly suggestive of LM, but like other inflammatory meningitides, it is confounding correct interpretation. Meningeal biopsy is

Address correspondence to: Marc C. Chamberlain, MD, Fred Hutchinson Cancer Center Seattle Cancer Care Alliance, 825 Eastlake Ave E, MS: G4-940, Seattle, WA 98109; Phone: 206-288-8280; Fax: 206-288-2000; E-mail: chambemc@u.washington.edu

rarely utilized, but in patients without a clear etiology for a CES, it may be indicated, as in the present case. As mentioned above, FDG-PET may provide evidence of extraneural disease not otherwise seen with computed tomography imaging and may demonstrate disease in the CNS not seen with MRI. As in the present case, a window of opportunity for treatment exists, and delay or failure to make the diagnosis in a timely manner may result in fulminant disease and clinical decline that is no longer responsive to therapy. Metastatic leptomeningeal disease in general is underrecognized, underdiagnosed, and undertreated, as this case report vividly illustrates.

## References

1. Mandawat A, Chadi Alraies M, Miller K, Ondrejka S, Smith S. Cauda equina lymphoma: a case report including postmortem examination. *Clin Adv Hematol Oncol.* 2011;9:414-418.
2. Kaal EC, Vecht CJ. CNS complications of breast cancer; current and emerging treatment options. *CNS Drugs.* 2007;21:559-579.
3. Grimm S, Chamberlain MC. Hodgkin's lymphoma: a review of neurologic complications. *Adv Hematol.* 2011;2011:624578.
4. Chamberlain MC. Leptomeningeal metastases. *Curr Opin Oncol.* 2010;22:627-635.
5. Gleissner B, Chamberlain MC. Treatment of CNS dissemination in systemic lymphoma. *J Neurooncol.* 2007;84:107-117.
6. Spector LR, Madigan L, Rhyne A, Darden B, Kim D. Cauda equina syndrome. *J Am Acad Orthop Surg.* 2008;16:471-479.
7. Lavy C, James A, Wilson-MacDonald J, Fairbank J. Cauda equina syndrome. *BMJ.* 2009;338:b936.
8. Fraser S, Roberts L, Murphy E. Cauda equina syndrome; a literature review of its definition and clinical presentation. *Arch Phys Med Rehabil.* 2009;90:1964-1968.