

Intracavitary Cidofovir for Human Herpes Virus-8–associated Primary Effusion Lymphoma in an HIV-negative Patient

Sorin Stingaciu, MD¹
 Michel Ticchioni, MD²
 Isabelle Sudaka, MD³
 Juliette Haudebourg, MD⁴
 Nicolas Mounier, MD, PhD¹

¹*Onco-Hematology Department, l'Archet Hospital;*
²*Immunology Department, l'Archet Hospital;* ³*Hematology Department, Cimiez Hospital;* ⁴*Pathology Department, Pasteur Hospital; Nice, France*

Introduction

Primary effusion lymphoma (PEL) is a rare type of non-Hodgkin lymphoma that mainly occurs in immunodeficient patients and is associated with infection by human herpes virus-8 (HHV-8). It develops in serous cavities, causing lymphomatous effusions in the absence of lymphadenopathy or organomegaly.^{1,2} Previous studies suggested that PEL occurs almost exclusively in HIV-infected patients. It was first described in association with Kaposi sarcoma.^{1,2} Subsequently, the authors of several studies demonstrated that PEL develops in non-AIDS patients with HHV-8 infection, suggesting that HHV-8 infection plays a key role in PEL.³

We report a rare case of HHV-8–positive PEL in an elderly, HIV-negative woman who presented with pleural effusion and was in clinical remission after intracavitary cidofovir. We also review the few recent reports of non-AIDS–related HHV-8–positive PEL.

Case Report

A 73-year-old, Mediterranean woman was hospitalized in December 2007 for dyspnea and thrombopenia. Her medical history included stage 1 breast cancer (1993), which had been treated with surgery, radiation, and hormone therapy (5 years of tamoxifen); diabetes; and systemic hypertension. The patient's performance status was 3. Physical examination revealed right axillary lymphadenopathy, and breath sounds were bilateral but reduced. Chest X-ray and a chest computed tomography (CT) scan

showed bilateral pleural effusions and right axillary lymph nodes; a CT scan of the abdomen revealed retroperitoneal lymph nodes with diameters of less than 3 cm, and splenomegaly (14 cm). The hemogram showed normocytic anemia (hemoglobin, 9.3 g/dL; platelets, $40 \times 10^9/L$; and leukocytes, $5.5 \times 10^9/L$, with 42% lymphocytes). Biochemistry showed elevated C-reactive protein (8 mg/L), hypoalbuminemia (21 g/L), and normal lactate dehydrogenase (319 U/L). Other biochemical data, including renal function, serum alanine aminotransferase, and bilirubin level were within normal limits. Serologic tests showed that hepatitis B virus (HBV) surface antigen, hepatitis C virus (HCV) antibody, and HIV antibody were all negative, but there was evidence of past infections by HHV-8 with immunoglobulin antibodies at 1,280 IU (N<160). Lymph axillary node biopsy only revealed reactive changes. Bone marrow biopsy was normal. The patient underwent pleurocentesis that produced 2,600 cm³ of fluid containing 43 g/L of protein. Cytologic analysis of the pleural effusion revealed large lymphoid cells with immature nuclei and a basophilic cytoplasm (Figure 1). Immunophenotyping (Figure 2) showed that the neoplastic cells were positive for leukocyte common antigens CD45, human leukocyte antigen (HLA)-DR–positive (85%), CD38–positive (75%), CD138–positive (33%), and CD30–positive (20%), as well as the absence of B-cell and T-cell markers. The polymerase chain reaction for HHV-8 was positive in blood and pleural fluid. PEL was diagnosed.

The patient was treated with 2 cycles of a full-dose CHOP regimen (750 mg/m² cyclophosphamide, 50 mg/m² doxorubicin, and 1.4 mg/m² vincristine on day 1, and 100 mg prednisone on days 1–5), resulting in normalization of the blood count but no improvement of the pleural effusion monitored with standard chest X-ray. Three months after the last cycle of CHOP, the patient

Address correspondence to:

Nicolas Mounier, MD, PhD, Onco-Hematology Department, l'Archet Hospital, 151 Route de Saint Antoine-Ginestière, 06000 Nice, France; Phone: 33 4 92 03 58 41; Fax: 33 4 92 03 58 95; E-mail: mounier.n@chu-nice.fr.

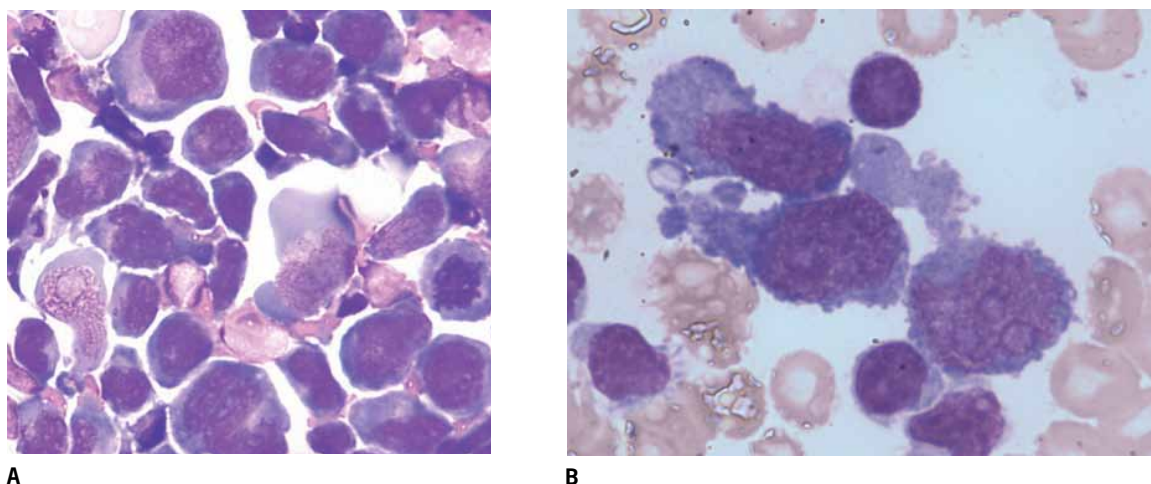


Figure 1. Pleural fluid. Panel A: (May-Grunwald-Giemsa stained, x 400) large lymphoid cell with basophilic cytoplasm, irregular nuclei, and prominent nucleoli. Panel B: (May-Grunwald-Giemsa stained, x 1,350), 3 noncohesive large immunoblastic or anaplastic cells, many with an abundant deeply basophilic cytoplasm and with several prominent nucleoli among the small lymphocytes in the background.

was treated with intrapleural cidofovir on the assumption that antiviral therapy directed against HHV-8 would eliminate PEL symptoms. Intrapleural cidofovir was administered into the right pleural space. Three weekly injections were given: the initial dose was 3 mg/kg and the 2 subsequent doses were 5 mg/kg each. There was no adverse reaction. The patient's performance status improved from 3 to 0, with total clearance of the pleural fluid as confirmed by the CT scan performed 3 months after the last injection (Figure 1). The patient has now been monitored for 18 months and remains in complete remission.

Discussion

PEL was first described in 1989 by Knowles and colleagues,⁴ and since then much has been learned about its unique pathogenesis, and more precisely the role of HHV-8.

In 1995, Cesarman and associates⁵ reported the presence of HHV-8 in AIDS-related body cavity–based lymphoma (BCBL). The term *PEL* was then suggested for AIDS-related and non-AIDS–related BCBLs, which are characterized by effusions in body cavities without lymphadenopathy, tumor masses, or bone marrow involvement, and typically are associated with HHV-8.⁵⁻¹⁰

HIV-seronegative patients with PEL might have an underlying immunodeficiency due to advanced age or associated conditions such as cirrhosis, cancer, or previous transplantation,⁸ or due to birth in areas with a high prevalence of HHV-8 infection, such as the Mediterranean region.^{11,12} HHV-8 is therefore thought to play a major

role in the pathogenesis of PEL. Patients with PEL are also frequently infected with Epstein-Barr virus (EBV), another type of HHV.^{1,13}

HHV-8 is a member of the gamma herpes virus family, which includes EBV. It was first characterized in 1994 in HIV-infected patients with Kaposi sarcoma.¹³ Subsequently, HHV-8 was found to be associated with other disorders, including PEL¹⁴ and multicentric Castleman disease.¹⁵ HHV-8 is a linear double-stranded DNA virus that is not ubiquitous, but has endemic areas of infection, including sub-Saharan Africa (seroprevalence of 50–70%) and the Mediterranean region (seroprevalence of 20–30%), whereas North America only exhibits a 1–3% rate of infection among asymptomatic blood donors.¹⁶ The exact mechanism by which HHV-8 promotes oncogenesis in PEL is currently under active investigation.

However, the discovery of HHV-8 did make it possible to differentiate PEL from all other known types of lymphoma because of its association with infection by this novel herpes virus. Although most studies on PEL pathogenesis have focused on HHV-8 and HIV, other unidentified viruses might be involved in PEL. The diagnosis of PEL rests upon the pathologic analysis of involved tissue using morphologic, immunophenotypic, molecular, and virologic criteria. The diagnosis is usually made from a cytologic preparation of the involved effusion fluid,¹⁷ as this fluid usually lacks a solid component.

Treatment of PEL is not well established because of its very low incidence. CHOP-like regimens are considered first-line therapy,^{18,19} but most PEL patients do not respond to CHOP therapy.¹⁸

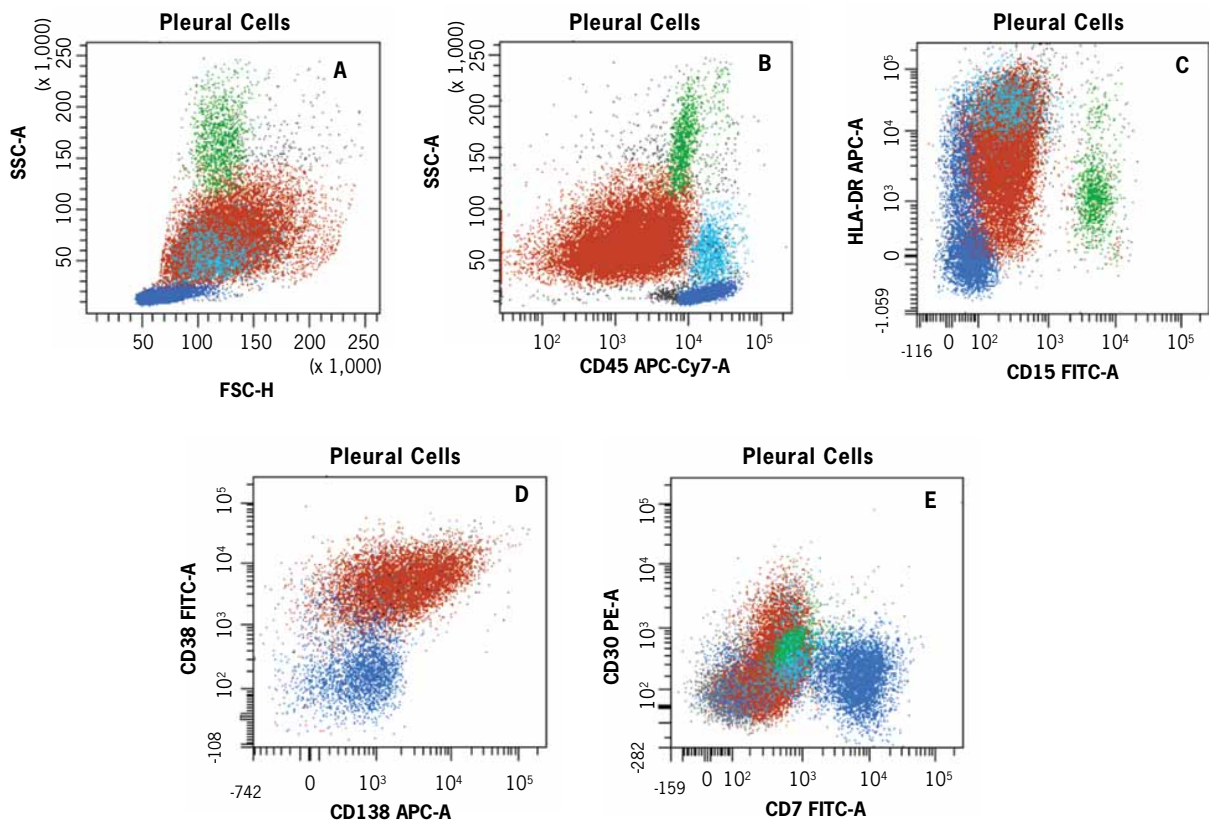


Figure 2. Flow cytometry appearance of lymphoma cells in pleural suffusion. Lymphoma cells are shown in red, monocytes in light blue, granulocytes in green, and lymphocytes in dark blue. Neoplastic cells are large cells with high granulometry, as shown in forward scatter (FSC) versus side scatter (SSC) dot blot (A). They exhibited weak expression of CD45 (B) and strong expression of HLA-DR (C) and CD38 (D). Weak expression of CD138 (D) and CD30 (E) was also detected. Myeloid, T- and B-cell markers were all negative.

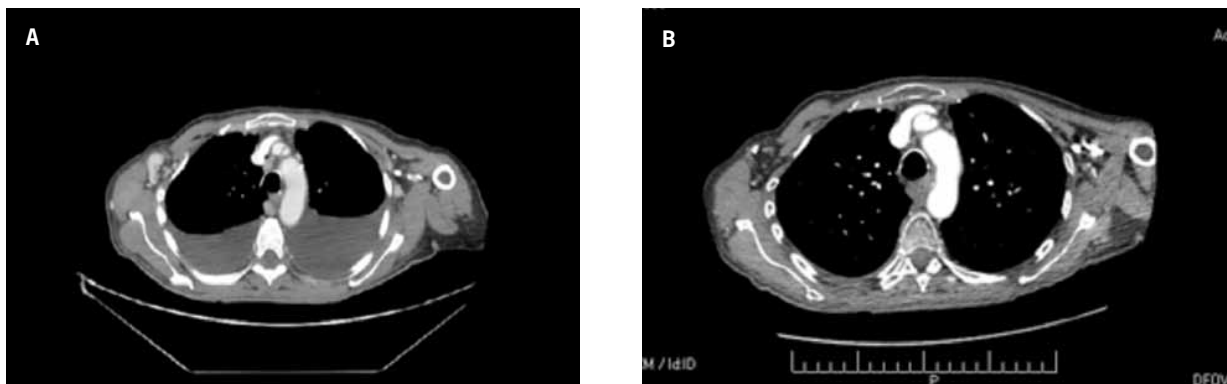


Figure 3. Chest computed tomography scan: (A) before cidofovir and (B) after 3 infusions of cidofovir.

Table 1. Clinical Features of 25 HIV-negative Patients With HHV-8–positive Primary Effusion Lymphoma

References	Age/sex	Origin	EBV	Kaposi sarcoma	Sites involved	Other disease	Treatment	Survival
Carbone, 1996 ⁷	69/F	Italy	(+)	No	Peritoneal	Cirrhosis	Chemotherapy	Died 1 mo
Nador, 1996 ¹	85/M	USA	(+)	No	Pleural	CHF	None	Died 6 mos
	78/M	USA	(+)	No	Pleural	NR	Unknown	Died 6 mos
Said, 1996 ²⁷	85/F	Russia	(-)	Yes	Pleural-bilateral	Leg amputation	None	Died 4 mos
Strauchen, 1996 ²⁸	94/M	NR	(-)	Yes	Pleural, peritoneal, pericardial	Large bowel carcinoma, hypertension	None	Died 4 yrs
Okada, 1998 ²⁹	101/M	Japan	(+)	No	Pleural-bilateral	CHF	Chemotherapy	Died 8 mos
Teruya-Feldstein, 1998 ³⁰	73/M	Portugal	(-)	No	Pleural-bilateral	CHF, Castelman disease	Chemotherapy	Died, time NR
Ascoli, 1999 ⁶	89/M	Italy	(-)	No	Pleural	Large bowel carcinoma, hypertension, malaria	Unknown	Lost to follow-up
	75/M	Italy	(-)	No	Pleural	Hypertension, CHF, myocardiopathy	None	Alive >4 yrs
San Miguel, 1999 ³¹	83/M	Spain	(-)	No	Pleural	Ischemic myocardiopathy, CHF	None	Died 3 d
Cobo, 1999 ³²	58/M	Morocco	(-)	No	Peritoneal	Cirrhosis	Chemotherapy	Died 3 mos
Ariad, 2000 ³³	68/M	Morocco/Jewish	(-)	No	Pleural, peritoneal	Ischemic cardiomyopathy	Chemotherapy	Died 8 mos
Codish, 2000 ³⁴	73/F	Russia/Jewish	(-)	Yes	Pleural	MCD, hypoglycemia	Chemotherapy	Died 16 mos
Polskj, 2000 ³⁵	80/M	USA	NR	No	Pleural-bilateral	NR	Chemotherapy	Alive 8 mos
Klepfish, 2001 ³	78/M	Eastern Europe	(-)	No	Pleural	CVA, hypertension	Chemotherapy	Died 18 mos
Perez, 2001 ³⁶	72/M	Argentina	(-)	NR	Pleural, peritoneal	NR	Rituximab	Alive 13 mos
Ascoli, 2002 ³⁷	92/M	Italy	(+)	No	Pleural-bilateral	CHF	None	Died 12 mos
	87/M	Italy	(+)	No	Pleural	CHF	IC-Cidofovir	Died 8 mos
	70/M	Italy	(-)	Yes	Pleural, peritoneal	KS	IC-Cidofovir	Alive >6 mos
Buonaiuto, 2002 ³⁸	92/M	Italy	NR	Yes	Pleural, peritoneal	KS	Chemotherapy	Died 3 mos
Boulanger, 2004 ¹¹	78/M	France	(-)	No	Peritoneal	CHF	Chemotherapy	Died 6 wks
	86/F	France	(-)	Yes	Peritoneal	Breast carcinoma, MCD	Chemotherapy	Died 2 mos
Halfdanarson, 2006 ³⁹	72/M	Italy	(+)	No	Pleural-bilateral	Fluctuating anemia	Chemotherapy, RT, IC-Cidofovir	Alive >15 mos
Hsieh, 2007 ⁴⁰	54/M	Taiwan	NR	NR	Pleural, peritoneal	Hepatitis B, cirrhosis	Chemotherapy, picibanil	Died 6 mos
Boulanger, 2008 ⁴¹	57/M	Mali	(-)	Yes	Pleural	Kidney transplant, KS	Chemotherapy	Died 8 mos
	63/M	Senegal	(-)	No	Pleural, peritoneal, pericardial	Kidney transplant	IV-Cidofovir	Died 8 d
Present case	73/F	France	(+)	No	Pleural-bilateral	Breast cancer, hypertension	Chemotherapy, IC-Cidofovir	Alive 18 mos

CHF=congestive heart failure; CVA=cerebral vascular accident; EBV=Epstein-Barr virus; IC=intracavitary; IV=intravenous; KS=Kaposi sarcoma; MCD=multicentric Castleman disease; NR=not reported; RT=radiotherapy.

The prognosis is poor,^{18,20} with very few long-term survivors, even with high-dose chemotherapy and autologous stem cell reinfusion.^{21,22} One recent, single-center series of 11 patients had a median survival time of 6 months,¹⁸ and for the most recent, large, multicenter series of 28 patients, median survival time was 6.2 months, and the 1-year overall survival rate was 39.3%.²⁰

Chemotherapy is generally unsatisfactory for these patients, partly because of their advanced age and frequent comorbid conditions. Cidofovir is an antiviral agent with a broad spectrum of activity against multiple DNA viruses. In vitro studies have shown that it is effective against HHV-8 and PEL cell lines.^{23,24} Recently, Luppi and coauthors reported 3 cases of elderly men with HIV-negative PEL who received intracavitary cidofovir (Table 1). All 3 patients responded, and the duration of their responses was 5–15 months. Intracavitary cidofovir may therefore constitute a reasonable choice of therapy in frail, elderly patients or in patients refractory to conventional chemotherapy. Inhibition of viral replication and a direct proapoptotic effect on lymphoma cells by cidofovir appear to have successfully controlled the malignant process.^{23,24} The cidofovir concentration needed to exert the proapoptotic effect is not achievable by intravenous administration of the drug, but a sufficiently high concentration may be achieved when it is delivered directly into the pleural cavity.

Thus, whether chemotherapy is the treatment of choice in PEL needs to be established. Targeting HHV-8 is a novel idea for treatment, but it has not yet been applied in clinical trials.^{25,26} At the present time, intracavitary cidofovir may be a reasonable choice of therapy for elderly patients or patients refractory to conventional chemotherapy.

Acknowledgement: The authors thank Mathilde Dreyfus for copyediting assistance.

References

- Nador RG, Cesarman E, Chadburn A, et al. Primary effusion lymphoma: a distinct clinicopathologic entity associated with the Kaposi's sarcoma-associated herpesvirus. *Blood*. 1996;88:645-656.
- Boulanger E, Agbalika F, Maarek O, et al. A clinical, molecular and cytogenetic study of 12 cases of human herpesvirus 8 associated with primary effusion lymphoma in HIV-infected patients. *Hematol J*. 2001;2:172-179.
- Klepfish A, Sarid R, Shtalrid M, et al. Primary effusion lymphoma (PEL) in HIV-negative patients—a distinct clinical entity. *Leuk Lymphoma*. 2001;41:439-443.
- Knowles D, Inghirami G, Ubriaco A, et al. Molecular genetic analysis of three AIDS-associated neoplasms of uncertain lineage demonstrates their B-cell derivation and the possible pathogenetic role. *Blood*. 1989;73:792-799.
- Cesarman E, Chang Y, Moore P, et al. Kaposi's sarcoma-associated herpesvirus-like DNA sequences in AIDS-related body cavity-based lymphomas. *N Engl J Med*. 1995;332:1186-1191.
- Ascoli V, Scalzo CC, Danese C, et al. Human herpesvirus 8-associated primary effusion lymphoma of the pleural cavity in HIV-negative elderly men. *Eur Respir J*. 1999;14:1231-1234.
- Carbone A, Gloghini A, Vaccher E, et al. Kaposi's sarcoma-associated herpesvirus DNA sequences in AIDS-related and AIDS-unrelated lymphomatous effusions. *Haematol*. 1996;332:1186-1191.
- Asou H, Said JW, Yang R, et al. Mechanisms of growth control of Kaposi's sarcoma-associated herpesvirus-associated primary effusion lymphoma cells. *Blood*. 1998;91:2475-2481.
- Cesarman E, Nador RG, Aozasa K, et al. Kaposi's sarcoma-associated herpesvirus in non-AIDS-related lymphomas occurring in body cavities. *Am J Pathol*. 1996;149:53-57.
- Teruya-Feldstein J, Zauber P, Setsuda JE, et al. Expression of human herpesvirus-8 oncogene and cytokine homologues in an HIV-seronegative patient with multicentric Castlemans disease and primary effusion lymphoma. *Lab Invest*. 1998;78:1637-1642.
- Boulanger E, Hermine O, Ferman J, et al. Human herpesvirus8 (HHV-8)-associated peritoneal primary effusion lymphoma (PEL) in two HIV-negative elderly patients. *Am J Hematol*. 2004;76:88-91.
- Gaidano G, Carbone A. Primary effusion lymphoma: a liquid phase lymphoma of fluid-filled body cavities. *Cancer Res*. 2001;61:115-146.
- Cesarman E, Chang Y, Moore PS, et al. Kaposi's sarcoma-associated herpesvirus-like DNA sequences in AIDS-related body-cavity-based lymphomas. *N Engl J Med*. 1995;332:1186-1191.
- Chang Y, Cesarman E, Pessin MS, et al. Identification of herpesvirus-like DNA sequences in AIDS-associated Kaposi's sarcoma. *Science*. 1994;266:1865-1869.
- Soulier J, Grollet L, Oksenhendler E, et al. Kaposi's sarcoma-associated herpesvirus-like DNA sequences in multicentric Castlemans disease. *Blood*. 1995;86:1276-1280.
- Dukers NH, Rezza G. Human herpesvirus 8 epidemiology: What we do and do not know. *AIDS*. 2003;17:1717-1730.
- Chen YB, Rahemtullah A, Hochberg E. Primary effusion lymphoma. *Oncologist*. 2007;12:569-576.
- Simonelli C, Spina M, Cinelli R, et al. Clinical features and outcome of primary effusion lymphoma in HIV-infected patients: a single-institution study. *J Clin Oncol*. 2003;21:3948-3954.
- Valencia ME, Martinez P, Moreno V, et al. AIDS-related body cavity-based lymphomas, herpesvirus-8 and HIV infection: a study of seven cases. *AIDS*. 1999;13:2603-2605.
- Boulanger E, Gerard L, Gabarre J, et al. Prognostic factors and outcome of human herpesvirus 8-associated primary effusion lymphoma in patients with AIDS. *J Clin Oncol*. 2005;23:4372-4380.
- Waddington TW, Aboulafia DM. Failure to eradicate AIDS-associated primary effusion lymphoma with high-dose chemotherapy and autologous stem cell reinfusion: case report and literature review. *AIDS Patient Care STDS*. 2004;18:67-73.
- Boulanger E, Daniel MT, Agbalika F, et al. Combined chemotherapy including high-dose methotrexate in KSHV/HHV8-associated primary effusion lymphoma. *Am J Hematol*. 2003;73:143-148.
- Kedes DH, Ganem D. Sensitivity of Kaposi's sarcoma-associated herpesvirus replication to antiviral drugs. Implications for potential therapy. *J Clin Invest*. 1997;99:2082-2086.
- Luppi M, Trovato R, Barozzi P, et al. Treatment of herpesvirus-associated primary effusion lymphoma with intracavity cidofovir. *Leukemia*. 2005;19:473-476.
- Klass CM, Offermann MK. Targeting human herpesvirus-8 for treatment of Kaposi's sarcoma and primary effusion lymphoma. *Curr Opin Oncol*. 2005;17:447-455.
- Cannon M, Cesarman E, Boshoff C. KSHV G protein coupled receptor inhibits lytic gene transcription in primary effusion lymphoma cells via p21-mediated inhibition of Cdk2. *Blood*. 2006;107:277-284.
- Said JW, Tasaka T, Takeuchi S, et al. Primary effusion lymphoma in women: report of two cases of Kaposi's sarcoma herpes virus-associated effusion-based lymphoma in human immunodeficiency virus-negative women. *Blood*. 1996;88:3124-3128.
- Strauchen JA, Hauser AD, Burstein D, et al. Body-cavity-based malignant lymphoma containing Kaposi's sarcoma-associated herpesvirus in an HIV-negative man with previous Kaposi sarcoma. *Ann Intern Med*. 1996;125:822-825.
- Okada T, Katano H, Tsutsumi H, et al. Body-cavity-based lymphoma in an elderly AIDS-unrelated male. *Int J Hematol*. 1998;67:417-422.
- Teruya-Feldstein J, Zauber P, Setsuda JE, et al. Expression of human herpesvirus-8 oncogene and cytokine homologues in an HIV-seronegative patient with multicentric Castlemans disease and primary effusion lymphoma. *Lab Invest*. 1998;78:1637-1642.

31. San Miguel P, Manzanal A, García Gonzalez G, et al. Association of body cavity-based lymphoma and human herpesvirus 8 in an HIV-seronegative male. Report of a case with immunocytochemical and molecular studies. *Acta Cytol.* 1999;43:299-302.
32. Cobo F, Hernandez S, Hernandez L, et al. Expression of potentially oncogenic HHV-8 genes in an EBV-negative primary effusion lymphoma occurring in an HIV-seronegative patient. *J Pathol.* 1999;189:288-293.
33. Ariad S, Benharroch D, Lupu L. Early peripheral lymph node involvement of human herpesvirus 8-associated, body cavity-based lymphoma in a human immunodeficiency virus-negative patient. *Arch Pathol Lab Med.* 2000;124:753-755.
34. Codish S, Abu-Shakra M, Ariad S, et al. Manifestations of three HHV-8-related diseases in an HIV-negative patient: immunoblastic variant multicentric Castlemans disease, primary effusion lymphoma, and Kaposi's sarcoma. *Am J Hematol.* 2000;65:310-314.
35. Polskj JM, Evans HL, Grosso LE, et al. CD7 and CD56-positive primary effusion lymphoma in a human immunodeficiency virus-negative host. *Leuk Lymphoma.* 2000;39:633-639.
36. Perez CL, Rudoy S. Anti-CD20 monoclonal antibody treatment of human herpesvirus 8-associated, body cavity based lymphoma with an unusual phenotype in a human immunodeficiency virus-negative patient. *Clin Diagn Lab.* 2001;8:993-996.
37. Ascoli V, Lo Coco F, Torelli G. Human herpesvirus 8-associated primary effusion lymphoma in human immunodeficiency virus-negative patients: a clinico-epidemiologic variant resembling classic Kaposi's sarcoma. *Haematologica.* 2002;87:339-343.
38. Buonaiuto D, Rossi D, Guidetti F, et al. Human herpesvirus type 8-associated primary lymphomatous effusion in an elderly HIV-negative patient: clinical and molecular characterization. *Ann Ital Med Int.* 2002;17:54-59.
39. Halfdanarson TR, Markovic SN, Kalokhe U, et al. A non-chemotherapy treatment of a primary effusion lymphoma: durable remission after intracavitary cidofovir in HIV negative PEL refractory to chemotherapy. *Ann Oncol.* 2006;17:1849-1855.
40. Hsieh PY, Huang SI, Li DK, et al. Primary effusion lymphoma involving both pleural and abdominal cavities in a patient with hepatitis B virus-related liver cirrhosis. *Formos Med Assoc.* 2007;106:504-508.
41. Boulanger E, Afonso PV, Yahiaouic Y, et al. Human herpesvirus-8 (HHV-8)-associated primary effusion lymphoma in two renal transplant recipients receiving rapamycin. *Am J Transplant.* 2008;8:707-710.

Review

Use of Cidofovir for the Treatment of HIV-negative Human Herpes Virus-8-associated Primary Effusion Lymphoma

Tamara K. Moyo, PhD,¹ Kristy L. Richards, MD, PhD,² and Blossom Damania, PhD¹

¹Department of Microbiology & Immunology;

²Department of Medicine, School of Medicine, Lineberger Comprehensive Cancer Center, University of North Carolina at Chapel Hill, Chapel Hill, North Carolina

Stingaciu and colleagues¹ report a case of an elderly, HIV-negative, Mediterranean woman diagnosed with primary effusion lymphoma (PEL) resistant to conventional chemotherapy. In addition to bilateral pleural effusion and decreased breath sounds, the patient also exhibited reactive changes in axillary and retroperitoneal lymph nodes. Cytologic and histologic analyses of the pleural fluid were consistent with a diagnosis of PEL. Human herpesvirus-8 (HHV-8) DNA was present in

pleural fluid, and antibodies to HHV-8 were detected in serum. The patient underwent 2 rounds of chemotherapy with cyclophosphamide, vincristine, doxorubicin, and prednisone (CHOP) with no improvement in her effusions or performance score. However, she exhibited complete and sustained remission after 3 doses of intracavitary cidofovir.

While the presence of HHV-8-infected lymphocytes is essential for diagnosis of PEL, malignant cells are commonly coinfecting with the closely related Epstein-Barr virus (EBV),^{2,3} as in this case study. The effect of dual herpesvirus infection is not well-defined with respect to either disease progression or response to treatment. Although this case report described HIV-negative PEL, more is known about PEL arising in the setting of HIV infection, which results in a poor prognosis. The average survival in HIV-positive patients with PEL is 6 months after diagnosis, despite conventional chemotherapy treatment.⁴⁻⁶ Noncompliance with highly active antiretroviral therapy has proven to be a poor prognostic factor in HIV-positive patients with PEL.^{5,6} Furthermore, patients with HIV and PEL may be less likely to tolerate the systemic side effects of conventional chemotherapies based on multiple comorbidities and poor performance score.⁵

The mainstay of treatment in PEL continues to be systemic, conventional, combinatorial, chemotherapeutic regimens such as CHOP,^{6,7} as administered in this case study. However, standard cytotoxic regimens are sub-optimal for several reasons. First, toxicity from effects on normal cells, including bone marrow suppression, gastrointestinal toxicity, and neurotoxicity, can limit the

Address correspondence to:

Blossom Damania, PhD, Lineberger Comprehensive Cancer Center, CB#7295, University of North Carolina, Chapel Hill, NC 27599; Phone: (919) 843-6011; Fax: (919) 966-9673; E-mail: damania@med.unc.edu.

benefit of these agents. Second, patients with PEL tend to have poorer immune function and performance status compared with other lymphoma patients, making them less likely to tolerate these side effects. Most importantly, systemic chemotherapy works very poorly in PEL, improving survival by a few months at best, with quick relapses even if there is an initial response. This poor response may be partially due to the sequestration of malignant cells within the body cavity where it may not experience high enough levels of cytotoxic agents to have a major direct effect. Newer strategies using radiation therapy or immunotherapy have also been attempted with only marginal improvement in outcomes.^{5,8-11}

The prospect of a specific antiviral agent is enticing, as it presumably would have fewer side effects caused by off-target effects. Cidofovir selectively inhibits the herpesviral DNA polymerase, thereby inhibiting viral DNA replication.¹² HHV-8 exists in both a latent and lytic life cycle in the infected host. The majority of HHV-8 tumors, including PEL, contain latent virus with a small percentage of the tumor cells undergoing lytic replication.¹³ The expression of lytic viral genes is thought to play a significant role in the tumorigenesis through the upregulation of paracrine and autocrine growth factors, which augment tumor proliferation and survival. Although cidofovir does not affect viral latency, it does inhibit the lytic phase of the virus and, thus, may repress the expression of lytic viral genes that contribute to tumor survival.¹⁴⁻¹⁶

Cidofovir has been shown to have direct cytotoxic effects on PEL cells in vitro.¹⁷ Although initial trials with intravenous cidofovir for the treatment of cutaneous Kaposi sarcoma—another HHV-8-associated malignancy—appeared successful,¹⁸ a larger, more recent report evidenced progression of disease in all 7 patients with intravenous administration of cidofovir for AIDS-related and classical Kaposi sarcoma.¹⁹ The data on intravenous administration of cidofovir (cidofovir-IV) for PEL are scant and also mixed. Complete remission has been documented in 2 HIV-positive patients with PEL when cidofovir-IV was combined with antiretroviral and interferon administration, while another patient achieved only partial remission and died after 6 months.^{3,20} The authors of this case study postulated that high enough concentrations of cidofovir were not achieved in the pleural fluid to affect direct cell killing when the drug was administered intravenously. Including this case report, 4 studies report achieving durable remission in HIV-negative patients with PEL with intracavitary cidofovir after conventional chemotherapy failure.²¹⁻²³ No reports were identified in which HIV-positive patients with PEL were treated with intracavitary cidofovir.

The main side effects of intravenous cidofovir include nephrotoxicity, neutropenia, and decreased intraocular pressure, and, thus, it is not a totally benign drug.^{24,25} However, it is possible that these ill effects may be lessened by the intracavitary route of administration, assuming systemic concentrations are lower, while still achieving concentrations in the effusion high enough to kill PEL cells and reduce the effusion. Indeed, in this case study, minimal side effects were noted by the patient. In summary, treatment of PEL with intracavitary cidofovir has the potential to be a more effective treatment strategy than standard chemotherapy regimens, and clinical trials using it in combination with frontline chemotherapy regimens are warranted.

References

1. Stingaciu S, Ticchioni M, Sudaka I, Haudebourg J, Mounier N. Intracavitary cidofovir for human herpes virus-8-associated primary effusion lymphoma in an HIV-negative patient. *Clin Adv Hematol Oncol*. 2010;8:367-372.
2. Cesarman E, Chang Y, Moore PS, Said JW, Knowles DM. Kaposi's sarcoma-associated herpesvirus-like DNA sequences in AIDS-related body-cavity-based lymphomas. *N Engl J Med*. 1995;332:1186-1191.
3. Boulanger E, Agbalika F, Maarek O, et al. A clinical, molecular and cytogenetic study of 12 cases of human herpesvirus 8 associated primary effusion lymphoma in HIV-infected patients. *Hematol J*. 2001;2:172-179.
4. Komanduri KV, Luce JA, McGrath MS, Herndier BG, Ng VL. The natural history and molecular heterogeneity of HIV-associated primary malignant lymphomatous effusions. *J Acquir Immune Defic Syndr Hum Retrovirol*. 1996;13:215-226.
5. Boulanger E, Gerard L, Gabarre J, et al. Prognostic factors and outcome of human herpesvirus 8-associated primary effusion lymphoma in patients with AIDS. *J Clin Oncol*. 2005;23:4372-4380.
6. Simonelli C, Spina M, Cinelli R, et al. Clinical features and outcome of primary effusion lymphoma in HIV-infected patients: a single-institution study. *J Clin Oncol*. 2003;21:3948-3954.
7. Valencia ME, Martinez P, Moreno V, Laguna F, Lahoz JG. AIDS-related body cavity-based lymphomas, herpesvirus-8 and HIV infection: a study of seven cases. *AIDS*. 1999;13:2603-2605.
8. Boulanger E, Daniel MT, Agbalika F, Oksenhendler E. Combined chemotherapy including high-dose methotrexate in KSHV/HHV8-associated primary effusion lymphoma. *Am J Hematol*. 2003;73:143-148.
9. Won JH, Han SH, Bae SB, et al. Successful eradication of relapsed primary effusion lymphoma with high-dose chemotherapy and autologous stem cell transplantation in a patient seronegative for human immunodeficiency virus. *Int J Hematol*. 2006;83:328-330.
10. Waddington TW, Aboulafia DM. Failure to eradicate AIDS-associated primary effusion lymphoma with high-dose chemotherapy and autologous stem cell reinfusion: case report and literature review. *AIDS Patient Care STDS*. 2004;18:67-73.
11. Re A, Cattaneo C, Michieli M, et al. High-dose therapy and autologous peripheral-blood stem-cell transplantation as salvage treatment for HIV-associated lymphoma in patients receiving highly active antiretroviral therapy. *J Clin Oncol*. 2003;21:4423-4427.
12. Lea AR, Bryson HM. Cidofovir. *Drugs*. 1996;52:225-230; discussion 231.
13. Asahi-Ozaki Y, Sato Y, Kanno T, Sata T, Katano H. Quantitative analysis of Kaposi sarcoma-associated herpesvirus (KSHV) in KSHV-associated diseases. *J Infect Dis*. 2006;193:773-782.
14. Medveczky MM, Horvath E, Lund T, Medveczky PG. In vitro antiviral drug sensitivity of the Kaposi's sarcoma-associated herpesvirus. *AIDS*. 1997;11:1327-1332.
15. Cesarman E. Kaposi's sarcoma-associated herpesvirus—the high cost of viral survival. *N Engl J Med*. 2003;349:1107-1109.
16. Grundhoff A, Ganem D. Inefficient establishment of KSHV latency suggests an additional role for continued lytic replication in Kaposi sarcoma pathogenesis. *J Clin Invest*. 2004;113:124-136.

17. Neyts J, De Clercq E. Antiviral drug susceptibility of human herpesvirus 8. *Antimicrob Agents Chemother*. 1997;41:2754-2756.
18. Mazzi R, Parisi SG, Sarmati L, et al. Efficacy of cidofovir on human herpesvirus 8 viraemia and Kaposi's sarcoma progression in two patients with AIDS. *AIDS*. 2001;15:2061-2062.
19. Little RF, Merced-Galindez F, Staskus K, et al. A pilot study of cidofovir in patients with kaposi sarcoma. *J Infect Dis*. 2003;187:149-153.
20. Hocqueloux L, Agbalika F, Oksenhendler E, Molina JM. Long-term remission of an AIDS-related primary effusion lymphoma with antiviral therapy. *AIDS*. 2001;15:280-282.
21. Halfdanarson TR, Markovic SN, Kalokhe U, Luppi M. A non-chemotherapy treatment of a primary effusion lymphoma: durable remission after intracavitary cidofovir in HIV negative PEL refractory to chemotherapy. *Ann Oncol*. 2006;17:1849-1850.
22. Luppi M, Trovato R, Barozzi P, et al. Treatment of herpesvirus associated primary effusion lymphoma with intracavity cidofovir. *Leukemia*. 2005;19:473-476.
23. Ascoli V, Lo Coco F, Torelli G, et al. Human herpesvirus 8-associated primary effusion lymphoma in HIV--patients: a clinicopathologic variant resembling classic Kaposi's sarcoma. *Haematologica*. 2002;87:339-343.
24. Lalezari JP, Stagg RJ, Kuppermann BD, et al. Intravenous cidofovir for peripheral cytomegalovirus retinitis in patients with AIDS. A randomized, controlled trial. *Ann Intern Med*. 1997;126:257-263.
25. Lalezari JP, Holland GN, Kramer F, et al. Randomized, controlled study of the safety and efficacy of intravenous cidofovir for the treatment of relapsing cytomegalovirus retinitis in patients with AIDS. *J Acquir Immune Defic Syndr Hum Retrovirol*. 1998;17:339-344.