

ADVANCES IN ONCOLOGY

Current Developments in the Management of Solid Tumor Malignancies

Section Editor: Clifford A. Hudis, MD

Colorectal Cancer In Focus

Role of Local Liver Therapy for Hepatic Metastases from Colorectal Cancer

Nancy Kemeny, MD
Professor of Medicine
Weill Medical College of Cornell University
Medical Oncologist
Memorial Sloan-Kettering Cancer Center
New York, New York

H&O What is local therapy and what are the available treatment options?

NK Before discussing local therapy, it is important to address why we may consider local therapy as a treatment option. In colon cancer, approximately 15–20% of patients have liver metastases at diagnosis, and approximately 60% of those patients who develop metastatic disease develop liver metastases during the treatment of their disease. The usual treatment for metastatic disease has been systemic chemotherapy, but in order to increase response rates, researchers have been investigating local liver therapies, which are defined as therapies that directly target liver tumors and the area surrounding them. Local therapy is used both in patients with liver metastases from colorectal cancer (CRC) and in patients with primary liver tumors such as hepatocellular carcinoma.

The types of local therapies used to treat liver metastases in CRC patients include hepatic arterial infusion (HAI), isolated hepatic perfusion, and radiofrequency ablation (RFA). Only results from our investigations with HAI will be discussed. HAI involves chemotherapy dispensed through a pump into a catheter that is inserted into an artery feeding the hepatic artery, to directly deliver medicine to the liver tumors. This pump is implanted under the skin (Figure 1). Isolated hepatic perfusion is a procedure in which a catheter is inserted into the hepatic artery and a second catheter is placed into the vein that

takes blood away from the liver. This results in a temporary separation of the liver's blood supply from the blood circulating throughout the rest of the body; this allows chemotherapy to directly target the liver. RFA is a method that utilizes heat to kill tumor cells. With RFA, needle electrodes are inserted into the tumor to heat and kill the tumor cells with radiofrequency energy. This procedure can be performed during open laparotomy by laparoscopic surgery, or percutaneously.

What we have been doing is combining systemic chemotherapy with HAI, which allows the liver to actually get double treatment. Because of this combined therapy to the liver, our ability to shrink tumors in the liver is very high (Figure 2). In a recently published study analyzing a combination of systemic chemotherapy and HAI, we reported a 92% response rate and a median survival of 41 months. In patients who were refractory to first-line chemotherapy, the study demonstrated an 85% response when using HAI plus systemic chemotherapy. The usual response with systemic therapy alone is less than 30% (Table 1).

Another situation in which HAI can be used is after liver resection. If a patient is suitable for liver resection, the patient has a 30% 5-year survival. Unfortunately, of those who undergo liver resection, in 70% the disease will recur in the liver or another site. However, by using HAI combined with systemic therapy after liver resection, there is a possibility to improve disease-free survival. An older study using HAI plus systemic fluorouracil (5-FU) plus leucovorin produced a 10-year survival rate of 41%. One of our recent phase I studies of systemic oxaliplatin, 5-FU, and leucovorin with HAI showed an 80% survival at 5 years after liver resection.

Table 1. Second-Line Therapy for Metastatic Colorectal Cancer

Systemic Tx	# Patients	% Response	1 Year Survival, %
CPT-11	205	11	46
CPT-11 + C225	218	23	–
FOLFOX	289	20	40
FOLFOX + Bev	290	22	55
CPT-11 + C225 + Bev	45	35	–

Bev=bevacizumab; CPT-11=irinotecan; C225=cetuximab; FOLFOX=5-FU, oxaliplatin, leucovorin.

HAI has also been used in patients with primary liver tumors such as cholangiocarcinomas. A study by Jarnagin and colleagues evaluated HAI in patients with intrahepatic cholangiocarcinoma or hepatocellular carcinoma. The findings demonstrated a 53.8% response rate in patients with intrahepatic cholangiocarcinoma. The median survival for the patients in this study was 29 months.

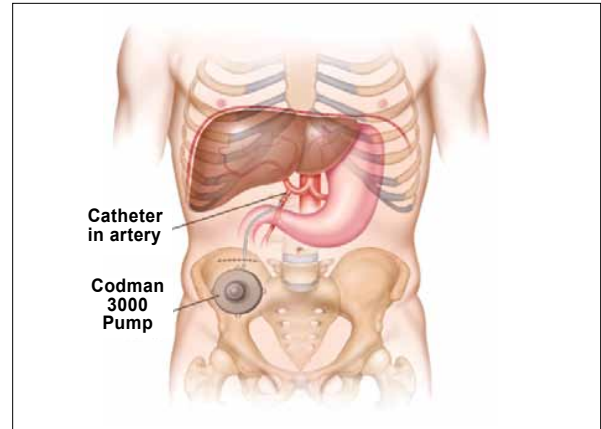
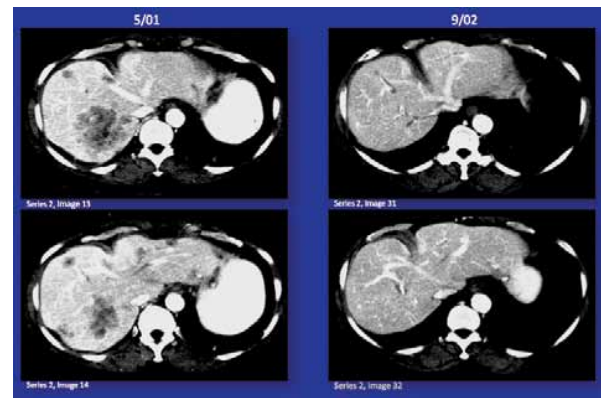
H&O What are the limitations of local therapy?

NK The challenge with infusion therapy such as HAI and isolated hepatic perfusion is that it requires a team. First, surgeons who are skilled in implanting pumps and catheters are needed because if these are not inserted correctly, perfusion occurs in other organs like the stomach or duodenum, which can result in ulcers. Second, nurses and medical oncologists who are trained to take care of patients and closely monitor liver function tests are needed. If the pump is not implanted correctly and perfusion to the stomach or duodenum occurs, then interventional radiologists are needed to embolize the vessel leading to the stomach/duodenum so that the pump can be used.

There are limitations to RFA as well. If it is performed near a blood vessel, a heat sink may develop and the procedure will not result in tumor cell death (the thermal energy will be conducted away from the tumor and will not kill tumor cells). This method also does not work well in large lesions (>3 cm).

H&O Which drugs are used in infusion therapy and which ones are used in systemic chemotherapy?

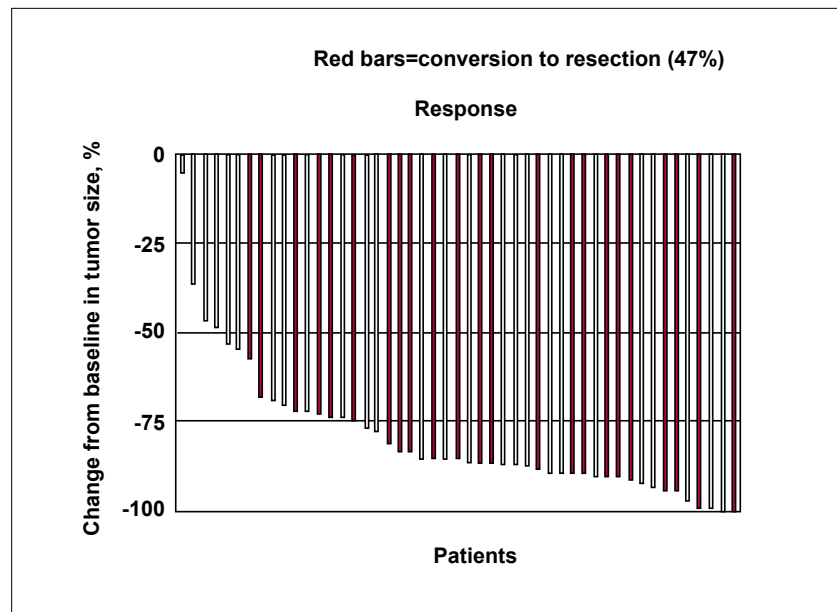
NK Floxuridine, dexamethasone, and 5-FU are frequently infused through HAI. Occasionally oxaliplatin

**Figure 1.** Diagram of hepatic arterial infusion.**Figure 2.** CT scans of female patient who, after progressing on irinotecan/5-FU/leucovorin, started hepatic arterial infusion treatment in May 2001 and underwent a liver resection in October 2002. No tumor was found at surgery. Now 7 years off therapy, the patient has no evidence of disease.

is used. Isolated percutaneous hepatic perfusion involves melphalan. The drugs that are administered as systemic chemotherapy have most frequently been oxaliplatin and irinotecan, as well as 5-FU.

Previous studies have evaluated HAI of dexamethasone with floxuridine and have found decreased hepatic toxicity with this combination. My colleagues and I recently published a study in which we determined the maximum tolerated dose of systemic oxaliplatin, 5-FU, and leucovorin given in combination with HAI of floxuridine and dexamethasone in the adjuvant setting after hepatic resection.

Figure 3. Colorectal cancer unresectable liver metastases. Hepatic arterial infusion of floxuridine/dexamethasone plus systemic irinotecan/oxaliplatin. Waterfall plot of percent tumor change from baseline.



H&O How often do we see conversion to resectability in patients with unresectable liver metastases?

NK Our surgeons believe that a patient in whom you can remove all the disease but leave at least 2 segments of the liver with good vascular supply is a resectable patient. Thus, our criteria of who is or is not resectable is more aggressive than some institutions. My colleagues and I recently published a study that evaluated conversion to resectability in patients with unresectable liver metastases from CRC. The patients in this study were treated with HAI and systemic oxaliplatin and irinotecan. We found that 57% of chemotherapy-naive patients with extensive disease were able to undergo resection. In previously treated patients, the resection rate was 38% (Figure 3).

H&O What do you think is the future role of local therapy?

NK Currently, I think physicians are very excited about the availability of new drugs, and we are expanding our arsenal of treatment options. However, our role is to do even better than we have done. At one point, we were solely using 5-FU, which produced low response rates

and survival. Then, we discovered new drugs that produced better survival rates. Going forward, I think it is important to consider a multidisciplinary approach to improving patient survival by incorporating improved staging and surgical techniques with novel therapies, and combining local and systemic therapies.

Suggested Readings

- Kemeny N, Huang Y, Cohen AM, et al. Hepatic arterial infusion of chemotherapy after resection of hepatic metastases from colorectal cancer. *N Engl J Med.* 1999;341:2039-2048.
- Kemeny NE, Melendez FD, Capanu M, et al. Conversion to resectability using hepatic artery infusion plus systemic chemotherapy for the treatment of unresectable liver metastases from colorectal carcinoma. *J Clin Oncol.* 2009;27:3465-3471.
- Kemeny N, Capanu M, D'Angelica M, et al. Phase I trial of adjuvant hepatic arterial infusion (HAI) with floxuridine (FUDR) and dexamethasone plus systemic oxaliplatin, 5-fluorouracil and leucovorin in patients with resected liver metastases from colorectal cancer. *Ann Oncol.* 2009;20:1236-1241.
- Jarnagin WR, Schwartz LH, Gultekin DH, et al. Regional chemotherapy for unresectable primary liver cancer: results of a phase II clinical trial and assessment of DCE-MRI as a biomarker of survival. *Ann Oncol.* 2009;20:1589-1595.
- Pingpank JF, Libutti SK, Chang R, et al. Phase I study of hepatic arterial melphalan infusion and hepatic venous hemofiltration using percutaneously placed catheters in patients with unresectable hepatic malignancies. *J Clin Oncol.* 2005;23:3465-3474.
- Ducreux M, Ychou M, Laplanche A, et al. Hepatic arterial oxaliplatin infusion plus intravenous chemotherapy in colorectal cancer with inoperable hepatic metastases: a trial of the gastrointestinal group of the Federation Nationale des Centres de Lutte Contre le Cancer. *J Clin Oncol.* 2005;23:4881-4887.