

VEGF Inhibitors in Brain Tumors

Priscilla K. Brastianos, MD, and Tracy T. Batchelor, MD, MPH

Dr. Brastianos is a Cancer Care Fellow in the Department of Medical Oncology at Dana-Farber/Brigham and Women's Cancer Center and in the Division of Hematology/Oncology at Massachusetts General Hospital. Dr. Batchelor is Associate Professor in the Department of Neurology at Harvard Medical School and Executive Director of Stephen E. and Catherine Pappas Center for Neuro-Oncology at Massachusetts General Hospital in Boston, Massachusetts.

Address correspondence to:
Tracy T. Batchelor, MD, MPH
Stephen E. and Catherine Pappas
Center for Neuro-Oncology
Yawkey 9E
Massachusetts General Hospital
Cancer Center
55 Fruit Street
Boston, Massachusetts 02114
Tel: 617-643-1938
Fax: 617-643-2591
E-mail: tbatchelor@partners.org

Keywords

Angiogenesis, vascular endothelial growth factor, malignant glioma, metastatic brain tumor, glioblastoma

Abstract: Glioblastomas are highly vascular tumors. Recent preclinical and clinical investigations have demonstrated that agents targeting angiogenesis may have efficacy in this type of tumor. Antibodies to vascular endothelial growth factor (VEGF), VEGF receptor tyrosine kinase inhibitors, immunomodulatory agents, and soluble decoy VEGF receptors are being studied in this patient population. Unfortunately, treatment inevitably fails. Further studies are needed to understand mechanisms of tumor resistance and to identify other therapeutic targets that mediate angiogenesis.

Introduction

The prognosis of patients with malignant brain tumors is poor despite advances in chemotherapy, surgery, and radiotherapy. Gliomas account for more than two-thirds of all brain tumors, with glioblastomas being the most frequent and malignant histologic glioma subtype.^{1,2} The 5-year survival rate of patients with glioblastomas is less than 3%.² The outlook for patients with metastatic disease to the brain is also poor, with median survival times ranging from several months to a few years, depending on the age and performance status of the patient, the tumor type, and the extent of metastatic disease.³ It is apparent that new treatment modalities are desperately needed.

In 1971, Judah Folkman proposed that angiogenesis, the formation of new blood vessels, is an important mechanism by which tumor growth occurs.⁴ Though this idea was initially met with resistance, extensive investigation over the last 3 decades has demonstrated the critical role of angiogenesis in the growth of solid tumors.^{5,6} Thirty-eight years after Dr. Folkman proposed his idea, there are 3 drugs approved by the U.S. Food and Drug Administration (FDA) that target angiogenesis. Bevacizumab (Avastin, Genentech), a humanized monoclonal antibody against vascular-endothelial growth factor (VEGF), is approved in combination with standard chemotherapy as first-line therapy for the treatment of non-small cell lung cancer, breast cancer, advanced colorectal cancer, and metastatic renal cell carcinoma. Bevacizumab has also received accelerated approval as monotherapy for recurrent glioblastoma.⁷⁻⁹ Sorafenib (Nexavar, Bayer), a multi-targeted (including VEGF) receptor kinase inhibitor, has been approved as a single agent in advanced renal cell and hepatocellular carcinoma.^{10,11} Sunitinib

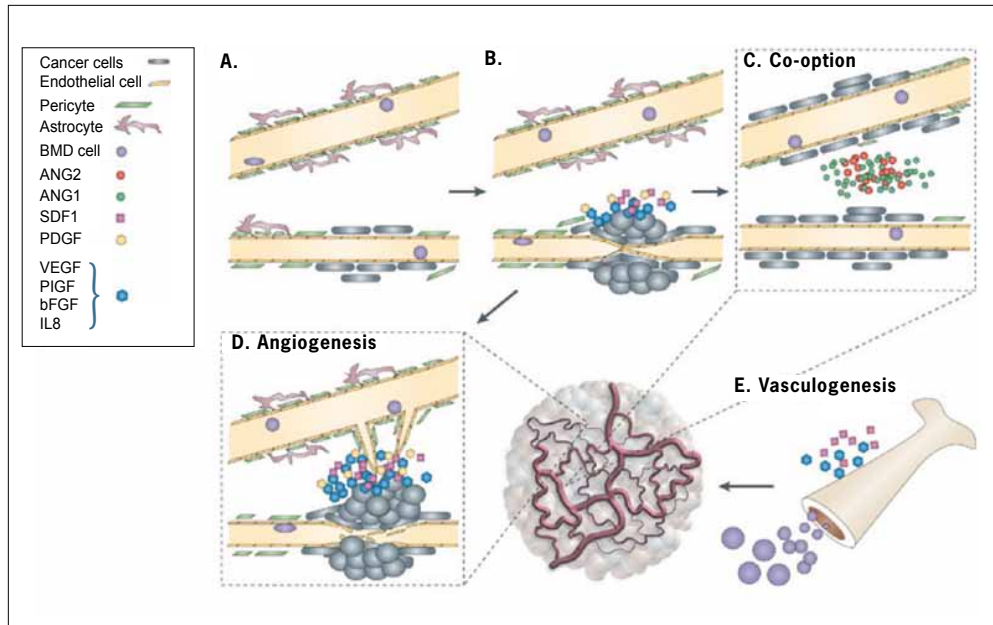


Figure 1. Schematic representation of different mechanisms of new blood vessel formation. A) Blood vessels are composed of astrocytes, pericytes, and endothelial cells. B) Tumor cells infiltrate along blood vessels. C) As the tumor grows, it co-opts normal capillaries using various cytokines. D) Blood vessels are compressed and destabilized, which decreases perfusion, and results in hypoxia. Hypoxic conditions result in increased secretion of several growth factors such as vascular endothelial growth factor (VEGF), stromal-cell-derived factor (SDF-1), basic fibroblast growth factor (bFGF), and Interleukin 8 (IL8). E) Bone-marrow-derived (BMD) cells and SDF-1 are recruited to induce vasculogenesis.

Reprinted from Jain et al. Angiogenesis in brain tumours. *Nat Rev Neurosci.* 2007;8:610-622.

(Sutent, Pfizer), also a multi-targeted (including VEGF) receptor kinase inhibitor, is approved for advanced renal cell carcinoma and gastrointestinal stromal tumors.^{12,13}

In this review we will summarize the role of angiogenesis in malignant brain tumors and then outline the experimental anti-VEGF therapies being studied in brain tumors. We will focus on therapies that are in later stages of development. Both primary and metastatic brain tumors will be reviewed, though most of the published data are from studies of malignant gliomas.

Angiogenesis and Brain Tumors

Malignant gliomas are highly vascular tumors and, like all solid tumors, require angiogenesis for their growth.¹⁴ A distinct histopathologic feature of glioblastoma is microvascular proliferation.¹⁵ The vasculature of glioblastomas is highly tortuous and disorganized, with abnormalities in vessel pericyte coverage, and basement membrane thickness.¹⁵⁻²⁰ The permeability of these vessels is increased, with the degree of permeability varying in a heterogeneous way, both temporally and spatially.²⁰⁻²² This abnormal permeability and morphologically aberrant vascular

network are associated with abnormal blood flow and heterogeneous delivery of oxygen, nutrients, and systemically administered drugs.²³ The tumor microenvironment created is characterized by areas of hypoxia, interstitial hypertension, and necrosis.²⁴⁻²⁸ As tumors grow beyond a diameter of 1–2 mm, the integrity of the blood brain barrier is disrupted both functionally and structurally.²⁰ The abnormal leakage and resultant contrast enhancement seen on computed tomography and magnetic resonance imaging scans of patients with glioblastomas is a result of this blood brain barrier disruption.

Glioblastomas utilize several mechanisms to form new vasculature (Figure 1). Initially tumor growth may occur by “co-option” of pre-existing, native blood vessels. Malignant cells migrate along normal blood vessels, structurally destabilizing them. This causes regression of these vessels, with decreased perfusion and local hypoxia.²⁹ The hypoxia triggers the secretion of pro-angiogenic cytokines.^{30,31} New vasculature may also form via vasculogenesis, whereby bone marrow-derived progenitor cells enter the circulation and are directly incorporated into vessels.³²

A number of complex and redundant molecular pathways drive angiogenesis. As tumor angiogenesis has

been reviewed in detail elsewhere, we will briefly summarize key features and focus our attention on the VEGF signaling axis. Glioblastomas produce several pro-angiogenic factors, which include VEGF,³³ platelet-derived growth factor (PDGF)- β ,³⁴ hepatocyte growth factor/scatter factor (HGF/SF),^{35,36} and basic fibroblast growth factor (bFGF).³⁷ VEGF-A (also referred to as VEGF), one of the key regulators of tumor angiogenesis, transduces its signal primarily through VEGF-receptor 2 (VEGFR-2), which is primarily located on the endothelial cell surface.^{5,38} VEGF expression may be increased by several factors. Hypoxic conditions increase expression and stabilize heterodimeric transcription factor HIF-1 α , which is a key mediator of the cellular response to hypoxia, by inducing transcription of many genes involved in cell survival and angiogenesis, including VEGF.³⁹ Higher levels of HIF-1 α and VEGF are associated with higher tumor grades.^{33,40} VEGF expression is also increased by nitric oxide, acidosis, other growth factors (eg, basic fibroblast growth factor, stem cell factor, epidermal growth factor, scatter factor/hepatocyte growth factor), loss of certain tumor suppression genes (eg, p53), and activation of oncogenes (eg, v-src).^{5,41-46} The binding of VEGF to VEGFR-2, with subsequent dimerization of the receptor, results in a cascade of intracellular molecular events culminating in endothelial cell proliferation, migration, and survival. These pathways include the mitogen-activated protein kinase (MAPK) and the phosphatidylinositol 3'-kinase (PI3K)-Akt pathways.^{5,47} VEGF also upregulates Notch Delta-like-ligand 4 (Dll4) expression. The Notch Dll pathway is an important stimulator of angiogenesis and is currently under investigation as a potential therapeutic target.⁵ Inhibition of Dll4 promotes nonproductive angiogenesis, resulting in increased hypoxia, poor perfusion, and decreased tumor growth.^{48,49}

VEGF also interacts with the angiopoietin pathway. Angiopoietin-1 (ang-1) and angiopoietin-2 (ang-2), an agonist/antagonist pair with significant sequence homology, are the major ligands that bind to and mediate signaling by Tie-2, a tyrosine kinase receptor expressed on endothelial cells.⁵⁰ In the presence of VEGF, the binding of ang-2 to Tie-2 promotes angiogenesis.⁵¹ In preclinical animal models of angiogenesis, ang-2 inhibition prevented VEGF-stimulated neovascularization.⁵¹ Further understanding of these pathways may enable the development of novel therapeutic agents.

Mechanism of Action of VEGF Inhibitors in Brain Tumors

The mechanism of action of anti-VEGF agents has not been completely elucidated, though several hypotheses have been suggested. Classically, VEGF inhibitors have

been thought to work by preventing new blood vessel growth, which deprives the tumor of oxygen and nutrients.⁵² A second potential mechanism of action is vascular normalization (Figure 2). According to this hypothesis, VEGF inhibitors may transiently normalize the tumor vascular network by 'pruning' immature vessels and improving their coverage with perivascular cells and basement membrane.^{16-19,53} This vascular normalization may improve the delivery of concurrent chemotherapeutic agents and enhance response to ionizing radiation.¹⁶⁻¹⁹

In mouse models of glioblastoma, VEGFR-2 inhibition produced a time window of reduced tumor hypoxia during which radiation had a synergistic effect with anti-VEGFR-2 therapy. During this normalization window, pericytes are recruited to blood vessels by activation of ang-1/Tie2 signaling. These vessels are more efficient at oxygen delivery, thus augmenting the effects of radiation.¹⁶⁻¹⁹

Finally, VEGF inhibitors may disrupt the interaction between endothelial cells and glioblastoma "stem-like" cells, which are the self-renewing cells that may give rise to gliomas. Disruption of the perivascular-stem cell niche may contribute to the death of these stem cells.^{54,55} Many anti-angiogenic agents, based on these proposed mechanisms of action, are currently under investigation for the treatment of brain tumors.

VEGF Antibodies

Bevacizumab

Bevacizumab is a recombinant humanized monoclonal antibody that neutralizes all isoforms of human VEGF. Thirty-three years after the concept of angiogenesis was introduced by Dr. Folkman, bevacizumab became the first drug that was developed as an angiogenesis inhibitor to be approved by the FDA.⁵ Several studies have demonstrated that bevacizumab may have activity against recurrent malignant gliomas. In case series of patients with recurrent malignant glioma treated with the combination of bevacizumab and conventional chemotherapy, radiographic response proportions ranging from 27–66% have been reported.⁵⁶⁻⁵⁹ In a study of 55 patients with recurrent glioblastoma, a 6-month progression-free survival (PFS) rate of 42% was observed,⁵⁷ which compares favorably to historical databases in this patient population, in which median 6-month PFS rates were 9–15%.⁶⁰ An anti-edema effect was also noted in these studies, with a reduction in corticosteroid requirements in approximately one-third of patients.⁵⁷ Bevacizumab was generally well-tolerated in these studies, with the most frequent complications being hemorrhagic and thromboembolic events.⁵⁶⁻⁵⁹ In a retrospective series of 77 patients treated with bevacizumab and irinotecan, complications included 5 intratumoral

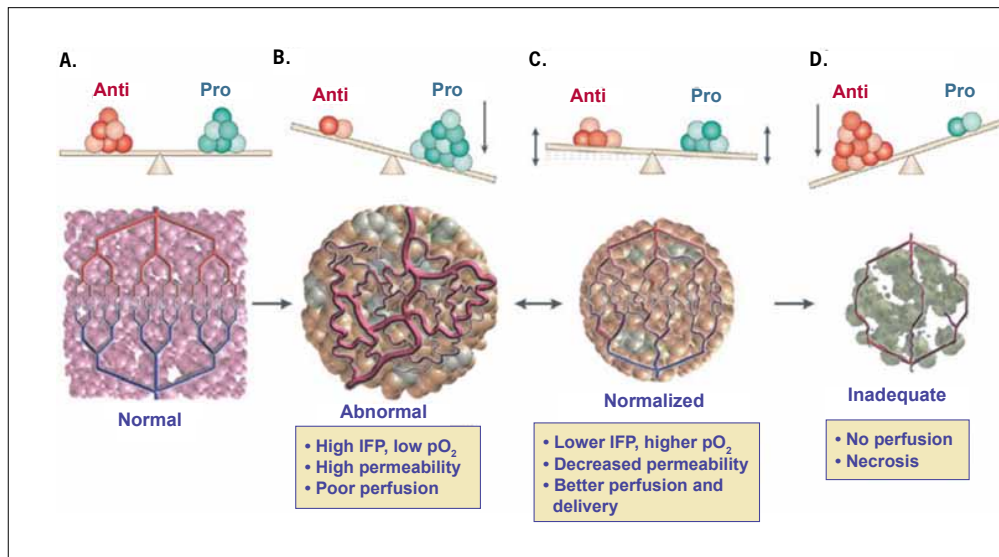


Figure 2. Schematic representation of mechanisms of anti-angiogenic treatment. A) Healthy tissues have balanced signaling from pro- and anti-angiogenic factors, and this results in an organized, effective vasculature. B) Tumors produce anti-angiogenic factors, which create a highly disorganized vascular network. C) Anti-angiogenic therapy can normalize the vasculature and allows for more effective delivery of drug. D) With potent anti-angiogenesis, the tumor is starved of nutrients and oxygen, with resulting necrosis of tumor.

IFP=interstitial fluid pressure; pO_2 =tissue oxygen level

Reprinted from Jain et al. Angiogenesis in brain tumours. *Nat Rev Neurosci.* 2007;8:610-622.

hemorrhages, 7 thromboembolic events, and 1 reversible leukoencephalopathy.⁵⁸

These promising results lead to the first prospective phase II trial of irinotecan and bevacizumab in recurrent grade III-IV gliomas, in which 68 patients were treated on 2 schedules. The radiographic response rate was 57% in glioblastoma patients. Clinical improvement was reported, along with a decrease in steroid requirements. The 6-month PFS rate was 43% in glioblastoma patients. Toxicities were similar to those reported in prior studies, and included 2 intracranial hemorrhages (3%) and 8 thromboembolic events (12%).⁶¹⁻⁶³ Similar promising results have been reported in subsequent prospective studies assessing the combination of bevacizumab and irinotecan.⁶⁴ In a phase II trial of 48 heavily pretreated patients with recurrent glioblastoma, patients were treated with bevacizumab initially, and with the combination of irinotecan and bevacizumab after tumor progression. The 6-month PFS rate was 29%, and median overall survival was 31 weeks.⁶⁵ In a noncomparative, randomized phase II study, 167 patients with recurrent glioblastoma were randomly assigned to receive bevacizumab with or without irinotecan.⁶⁶ The 6-month PFS rate was 50% in the combination therapy arm and 35% in the bevacizumab arm. The majority of patients had at least

a 50% reduction in their corticosteroid dose. Median survival was 8.9 months in the combination arm and 9.7 months in the bevacizumab-alone arm.⁶⁶ Patients receiving the combination therapy had a higher rate of grade 3 toxicities than those receiving bevacizumab alone (67% vs 48%). Further studies are warranted to investigate whether the addition of irinotecan confers a significant advantage when compared to bevacizumab alone.

Based on the results of these trials, bevacizumab has been approved for use as a single agent in recurrent glioblastoma. A number of trials are now underway to evaluate the efficacy of bevacizumab in combination with other agents for patients with recurrent, as well as newly diagnosed, glioblastoma.

VEGF-Trap

Aflibercept (VEGF-Trap, Regeneron) is a potent, high-affinity, soluble decoy VEGF receptor fused to an immunoglobulin constant region that inhibits tumor growth when studied in preclinical glioma models.^{67,68} Preliminary data from a single-arm, phase II trial of aflibercept in patients with recurrent malignant glioma demonstrated response proportions of 30% in glioblastoma and 50% in grade III gliomas. However, there was treatment-related discontinuation of therapy in 25% of patients because of

toxicity.⁶⁹ There are ongoing trials of aflibercept in combination with radiation and temozolomide in newly diagnosed glioblastoma and in recurrent malignant glioma.

Tyrosine Kinase Inhibitors

Cediranib

Cediranib (Recentin, AstraZeneca) is a potent pan-VEGF receptor tyrosine kinase receptor with additional activity against c-Kit and PDGF receptors.⁵³ In a phase II study, recurrent glioblastoma patients were treated with cediranib monotherapy, with 17 of 30 patients achieving objective partial radiographic responses and a 6-month PFS proportion of 26%. The majority of patients had their steroid doses decreased or discontinued altogether after initiation of cediranib. Cediranib was generally well tolerated, with treatment-related discontinuation of therapy in 2 of 31 patients. Toxicities included diarrhea, fatigue, and hypertension. Notably, there were no intracranial hemorrhages observed.⁵³ MRI techniques demonstrated reduction in tumor-associated edema and tumor vasculature normalization in patients receiving cediranib.^{53,70} A phase III study investigating the combination of cediranib and lomustine in recurrent glioblastoma is ongoing (Table 1).

Vatalanib

Vatalanib (PTK787, Novartis) is an oral pan-VEGFR, c-Kit, and PDGFR tyrosine kinase inhibitor that was investigated for the treatment of newly diagnosed and recurrent malignant gliomas. Preclinical models have shown that vatalanib halts VEGF-mediated glioma growth.⁷¹ When investigated as monotherapy in a phase I/II clinical trial of patients with recurrent glioblastoma, vatalanib produced radiographic responses in 4% of patients and stable disease in 56%. Dose-limiting toxicities included transaminitis, nausea/vomiting, cerebral edema, fatigue, and deep-vein thrombosis.⁷² A phase I study of vatalanib plus imatinib (Gleevec, Novartis) and hydroxyurea in recurrent malignant gliomas demonstrated that vatalanib doses of up to 1,000 mg twice/day were well tolerated. Dose-limiting toxicities were hematologic (cytopenias), renal, and gastrointestinal. Of note, no patients developed intracranial hemorrhages. Twenty-four percent of patients achieved a partial radiographic response and 49% of patients achieved disease stability.^{73,74} Despite these encouraging data in glioblastoma patients, the drug will not be further developed by the manufacturer.

Other Tyrosine Kinase Inhibitors

Sorafenib (Nexavar, Bayer) is a multitargeted kinase inhibitor with activity against many kinases including VEGFR, PDGFR, c-Kit, Ret, and Raf.⁷⁵ Sorafenib has antiproliferative activity in vitro against malignant glioma

cell lines.⁷⁶ A phase I trial demonstrated that sorafenib is well-tolerated in patients with recurrent malignant glioma.⁷⁷ Further studies with sorafenib are underway. Clinical studies using other VEGF receptor inhibitors, including sunitinib, AEE788 (Novartis), and vandetanib (ZD6474, AstraZeneca), are also ongoing (Table 1).

Immunomodulatory Agents

Thalidomide and Lenalidomide

Thalidomide (Thalomid, Celgene) has been investigated as a potential anti-angiogenic therapy in various cancers including gliomas and brain metastases. Thalidomide has potent anti-angiogenic activity in preclinical models.^{78,79} The immunomodulatory effects of thalidomide are believed to be mediated through the inhibition of tumor necrosis factor,⁸⁰ but this mechanism is not thought to be responsible for its anti-angiogenic activity. The mechanism of action is unclear, but is possibly due to the inhibition of VEGF and bFGF.^{81,82}

When thalidomide has been used as monotherapy in recurrent glioblastoma patients, results have been disappointing, with partial radiographic response proportions of only 5–6%.^{81,83,84} Combination therapies have also been studied. Thalidomide, when combined with temozolomide (Temodar, Schering-Plough), had little activity in recurrent gliomas.⁸⁵ Adding thalidomide to the combination of temozolomide and radiation therapy in newly diagnosed glioblastoma patients also did not confer a survival advantage,⁸⁶ nor did the combination of temozolomide, thalidomide, and celecoxib.⁸⁷ However, the combination of carmustine and thalidomide was associated with a radiographic response proportion of 24% in a phase II trial, which compares favorably to historical controls.⁸⁸ Lenalidomide (Revlimid, Celgene), a more potent thalidomide analog with greater anti-angiogenic activity, did not appear to have efficacy in a phase I trial in combination with radiation in newly diagnosed glioblastoma patients.⁸⁹ Activity was also limited when it was used as monotherapy in patients with recurrent malignant glioma.⁹⁰

In addition to being studied in glioma patients, thalidomide has also been evaluated in patients with brain metastases. In a phase III study, patients with multiple brain metastases were randomized to receive conventional whole-brain radiation therapy plus thalidomide versus whole-brain radiation therapy alone. Median survival in both groups was 3.9 months. Thalidomide was not well-tolerated, with discontinuation of therapy in 48% of patients secondary to side effects.⁹¹ A phase II study of thalidomide as a single agent in patients with metastatic melanoma to the brain demonstrated limited activity.⁹² The combination of thalidomide, temozolomide, and

Table 1. Select Anti-vascular Endothelial Growth Factor Agents Currently in Clinical Trials for Glioblastoma*

Drug	Mechanism	Trial Population	Phase	Combination
Antibodies				
Aflibercept	VEGF-A,-B, placental growth factor “receptor decoy”	Recurrent GBM	II	
Bevacizumab	VEGF-A antibody	Newly diagnosed GBM or gliosarcoma stable following RT and TMZ	II	BVB + erlotinib + TMZ
		Recurrent glioblastoma	II	Bevacizumab + temozolomide
		Newly diagnosed GBM	II	Concurrent RT, TMZ + BVB followed by BVB/everolimus
		Newly diagnosed GBM	II	BVB, irinotecan, RT vs BVB, TMZ, RT
		Newly diagnosed GBM	III	TMZ + RT + BVB vs TMZ +RT
VEGF receptor inhibitors				
AEE788	VEGFR-1,2, EGFR inhibitor	Recurrent GBM	I/II	Everolimus
		Recurrent GBM	I/II	
CT-322	VEGFR-1–3 inhibitor	Newly diagnosed GBM	I	RT + TMZ
Cediranib	VEGFR-1–3, PDGFR β , c-kit inhibitor	Recurrent GBM	III	Versus lomustine
Pazopanib	VEGFR-1–3, PDGFR β , c-kit inhibitor	Recurrent GBM	II	
Sorafenib	VEGFR-2,3, BRAF, PDGFR β , c-Kit, Ras, p38 α inhibitor	Newly diagnosed GBM or gliosarcoma	I/II	RT + TMZ
	VEGFR-2, PDGFR β , c-Kit, Flt3 inhibitor	Recurrent GBM	I/II	Erlotinib, tipifarnib or temsirolimus
Sunitinib	VEGFR-2, PDGFR β , c-Kit, Flt3 inhibitor	Recurrent GBM	II	
Vandetanib (ZD6474)	VEGFR-2, EGFR	Recurrent high-grade and progressive low-grade glioma	I/II	EIAEDs
		Newly diagnosed GBM	I/II	TMZ + RT
		Recurrent MG	I	Etoposide
		Recurrent MG	I	Imatinib and hydroxyurea
Vatalanib (PTK787)	VEGFR1–3,PDGFR β , c-kit inhibitor	Newly diagnosed GBM	I	TMZ + RT + vatalanib in patients taking EIAEDs
Immunomodulatory agents				
Lenalidomide	Unknown	Recurrent GBM	I/II	Irinotecan
Thalidomide	Unknown	Newly diagnosed GBM	II	RT followed by TMZ, thalidomide, celecoxib

*Please see the National Institutes of Health's ClinicalTrials.gov website for information regarding ongoing trials (<http://www.clinicaltrials.gov>).

BVB=bevacizumab; EGFR=epithelial growth factor receptor; EIAEDs=enzyme-inducing anti-epileptic drugs; GBM=glioblastoma; MG=malignant gliomas; PDGFR=platelet-derived growth factor receptor; RT=radiation therapy; TMZ=temozolomide; VEGFR=vascular endothelial growth factor receptor.

whole-brain radiation therapy produced little efficacy in patients with central nervous system metastases from melanoma.⁹³ Several clinical trials are underway to further investigate thalidomide and lenalidomide in malignant gliomas as well as in metastatic brain tumors.

Anti-edema Effects

Primary and metastatic brain tumors are often associated with a significant amount of vasogenic edema due to the highly permeable vessels formed within these tumors. Vasogenic brain edema is a primary reason why a large proportion of brain tumor patients require treatment, often long-term, with corticosteroids. Studies have demonstrated a decrease in vascular permeability in patients treated with anti-VEGF agents, specifically with cediranib, vatalanib, and bevacizumab.^{53,59,62,72,94} In a recent phase II study of cediranib in patients with recurrent glioblastoma, a reduction in tumor-associated edema was demonstrated with MRI.⁵³ The effects of cediranib were also evaluated in 3 different orthotopic glioblastoma mouse models, which showed that cediranib significantly alleviated edema through rapid normalization of tumor vasculature.⁹⁵ Of note, survival time was significantly prolonged with no change in tumor growth, indicating that a potent anti-edema effect may prolong survival in these particular orthotopic glioma models.⁹⁵

Resistance to Anti-angiogenic Therapy

Though anti-angiogenic agents are associated with clinical benefit, the effects are transitory at best. Most patients treated with anti-angiogenic agents eventually experience tumor progression. Evidence is emerging that tumors develop an adaptive response to angiogenesis inhibitors.⁹⁶ Postulated mechanisms for this resistance include upregulation of alternative pro-angiogenic pathways, improved protection of tumor vasculature by increasing pericyte coverage, recruitment of vascular progenitor cells from the bone marrow, and enhanced ability of tumor cells to invade without angiogenesis.⁹⁶ Furthermore, some tumors have a pre-existing, intrinsic resistance to anti-angiogenic agents via activation of redundant, VEGF-independent, pro-angiogenic pathways.⁹⁶ This may explain why a substantial minority of patients in clinical trials fail to demonstrate even a minor response to anti-VEGF therapy. Further investigation is needed to understand both the adaptive and the pre-existing intrinsic pathways that enable a tumor to evade anti-angiogenic therapy.

Monitoring Response to Anti-angiogenic Agents

Conventionally, response to therapy has been assessed by monitoring the extent of contrast enhancement on CT and MRI scans. Glioblastomas enhance because contrast agents administered intravenously leak into the brain parenchyma in the setting of blood brain barrier dysfunction. Anti-VEGF agents decrease the permeability of the tumor vasculature, thereby reducing contrast leakage on post-contrast T1-weighted MRI scans.⁵³ This makes interpretation of post-treatment images challenging. Alternative imaging sequences may be useful in the detection of progressive tumors in the setting of anti-VEGF therapy. Diffusion imaging is one such promising modality with areas of restricted diffusion possibly correlating with progressive, infiltrative tumor.^{64,97-99} New radiographic response criteria are under development for the assessment of efficacy of anti-VEGF therapies in brain tumor patients.¹⁰⁰

Conclusion

Angiogenesis is a complex molecular process that is incompletely understood. Recent preclinical and clinical investigations have demonstrated that anti-VEGF agents, either alone or in combination with chemotherapy, may have efficacy in the treatment of malignant brain tumors. To date, these agents have been associated with prolonged PFS and reduction of vasogenic brain edema. Larger prospective trials are underway to validate these results and to assess the impact on patient survival. Unfortunately, in most patients, treatment inevitably fails. Further studies are needed to target other pro-angiogenic signaling pathways. New neuro-imaging techniques are essential to accurately assess tumor response to anti-VEGF therapy. Nevertheless, inhibition of angiogenesis is a promising therapeutic approach that has the potential to have a significant impact on the treatment of both metastatic and primary brain tumors.

References

- Ohgaki H, Kleihues P. Epidemiology and etiology of gliomas. *Acta Neuropathol.* 2005;109:93-108.
- Ohgaki H. Epidemiology of brain tumors. *Methods Mol Biol.* 2009;472:323-342.
- Golden DW, Lamborn KR, McDermott MW, et al. Prognostic factors and grading systems for overall survival in patients treated with radiosurgery for brain metastases: variation by primary site. *J Neurosurg.* 2008;109 Suppl:77-86.
- Folkman J. Tumor angiogenesis: therapeutic implications. *N Engl J Med.* 1971;285:1182-1186.
- Kerbel RS. Tumor angiogenesis. *N Engl J Med.* 2008;358:2039-2049.
- Carmeliet P, Baes M. Metabolism and therapeutic angiogenesis. *N Engl J Med.* 2008;358:2511-2512.

7. Miller K, Wang M, Gralow J, et al. Paclitaxel plus bevacizumab versus paclitaxel alone for metastatic breast cancer. *N Engl J Med*. 2007;357:2666-2676.
8. Sandler A, Gray R, Perry MC, et al. Paclitaxel-carboplatin alone or with bevacizumab for non-small-cell lung cancer. *N Engl J Med*. 2006;355:2542-2550.
9. Hurwitz H, Fehrenbacher L, Novotny W, et al. Bevacizumab plus irinotecan, fluorouracil, and leucovorin for metastatic colorectal cancer. *N Engl J Med*. 2004;350:2335-2342.
10. Escudier B, Eisen T, Stadler WM, et al. Sorafenib in advanced clear-cell renal-cell carcinoma. *N Engl J Med*. 2007;356:125-134.
11. Llovet JM, Ricci S, Mazzaferro V, et al. Sorafenib in advanced hepatocellular carcinoma. *N Engl J Med*. 2008;359:378-390.
12. Motzer RJ, Hutson TE, Tomczak P, et al. Sunitinib versus interferon alfa in metastatic renal-cell carcinoma. *N Engl J Med*. 2007;356:115-124.
13. Demetri GD, van Oosterom AT, Garrett CR, et al. Efficacy and safety of sunitinib in patients with advanced gastrointestinal stromal tumour after failure of imatinib: a randomised controlled trial. *Lancet*. 2006;368:1329-1338.
14. Brem S, Cotran R, Folkman J. Tumor angiogenesis: a quantitative method for histologic grading. *J Natl Cancer Inst*. 1972;48:347-356.
15. Kargiotis O, Rao JS, Kyritsis AP. Mechanisms of angiogenesis in gliomas. *J Neurooncol*. 2006;78:281-293.
16. Winkler F, Kozin SV, Tong RT, et al. Kinetics of vascular normalization by VEGFR2 blockade governs brain tumor response to radiation: role of oxygenation, angiopoietin-1, and matrix metalloproteinases. *Cancer Cell*. 2004;6:553-563.
17. Jain RK. Normalizing tumor vasculature with anti-angiogenic therapy: a new paradigm for combination therapy. *Nat Med*. 2001;7:987-989.
18. Jain RK. Normalization of tumor vasculature: an emerging concept in antiangiogenic therapy. *Science*. 2005;307:58-62.
19. Tong RT, Boucher Y, Kozin SV, Winkler F, Hicklin DJ, Jain RK. Vascular normalization by vascular endothelial growth factor receptor 2 blockade induces a pressure gradient across the vasculature and improves drug penetration in tumors. *Cancer Res*. 2004;64:3731-3736.
20. Jain RK, di Tomaso E, Duda DG, Loeffler JS, Sorensen AG, Batchelor TT. Angiogenesis in brain tumours. *Nat Rev Neurosci*. 2007;8:610-622.
21. Monsky WL, Fukumura D, Gohongi T, et al. Augmentation of transvascular transport of macromolecules and nanoparticles in tumors using vascular endothelial growth factor. *Cancer Res*. 1999;59:4129-4135.
22. Hobbs SK, Monsky WL, Yuan F, et al. Regulation of transport pathways in tumor vessels: role of tumor type and microenvironment. *Proc Natl Acad Sci U S A*. 1998;95:4607-4612.
23. Jain RK, Tong RT, Munn LL. Effect of vascular normalization by antiangiogenic therapy on interstitial hypertension, peritumor edema, and lymphatic metastasis: insights from a mathematical model. *Cancer Res*. 2007;67:2729-2735.
24. Helmlinger G, Yuan F, Dellian M, Jain RK. Interstitial pH and pO₂ gradients in solid tumors in vivo: high-resolution measurements reveal a lack of correlation. *Nat Med*. 1997;3:177-182.
25. Yuan F, Salehi HA, Boucher Y, Vasthare US, Tuma RF, Jain RK. Vascular permeability and microcirculation of gliomas and mammary carcinomas transplanted in rat and mouse cranial windows. *Cancer Res*. 1994;54:4564-4568.
26. Boucher Y, Leunig M, Jain RK. Tumor angiogenesis and interstitial hypertension. *Cancer Res*. 1996;56:4264-4266.
27. Rampling R, Cruickshank G, Lewis AD, Fitzsimmons SA, Workman P. Direct measurement of pO₂ distribution and bioreductive enzymes in human malignant brain tumors. *Int J Radiat Oncol Biol Phys*. 1994;29:427-431.
28. Rong Y, Durden DL, Van Meir EG, Brat DJ. 'Pseudopalisading' necrosis in glioblastoma: a familiar morphologic feature that links vascular pathology, hypoxia, and angiogenesis. *J Neuropathol Exp Neurol*. 2006;65:529-539.
29. Holash J, Maisonpierre PC, Compton D, et al. Vessel cooption, regression, and growth in tumors mediated by angiopoietins and VEGF. *Science*. 1999;284:1994-1998.
30. Zagzag D, Amirnovin R, Greco MA, et al. Vascular apoptosis and involution in gliomas precede neovascularization: a novel concept for glioma growth and angiogenesis. *Lab Invest*. 2000;80:837-849.
31. Yancopoulos GD, Davis S, Gale NW, Rudge JS, Wiegand SJ, Holash J. Vascular-specific growth factors and blood vessel formation. *Nature*. 2000;407:242-248.
32. Duda DG, Cohen KS, Kozin SV, et al. Evidence for incorporation of bone marrow-derived endothelial cells into perfused blood vessels in tumors. *Blood*. 2006;107:2774-2776.
33. Plate KH, Breier G, Weich HA, Risau W. Vascular endothelial growth factor is a potential tumour angiogenesis factor in human gliomas in vivo. *Nature*. 1992;359:845-848.
34. Tsai JC, Goldman CK, Gillespie GY. Vascular endothelial growth factor in human glioma cell lines: induced secretion by EGF, PDGF-BB, and bFGF. *J Neurosurg*. 1995;82:864-873.
35. Schmidt NO, Westphal M, Hagel C, et al. Levels of vascular endothelial growth factor, hepatocyte growth factor/scatter factor and basic fibroblast growth factor in human gliomas and their relation to angiogenesis. *Int J Cancer*. 1999;84:10-18.
36. Abounader R, Lateral J. Scatter factor/hepatocyte growth factor in brain tumor growth and angiogenesis. *Neuro Oncol*. 2005;7:436-451.
37. Stefanik DF, Rizkalla LR, Soi A, Goldblatt SA, Rizkalla WM. Acidic and basic fibroblast growth factors are present in glioblastoma multiforme. *Cancer Res*. 1991;51:5760-5765.
38. Millauer B, Shawver LK, Plate KH, Risau W, Ullrich A. Glioblastoma growth inhibited in vivo by a dominant-negative Flk-1 mutant. *Nature*. 1994;367:576-579.
39. Kaur B, Khwaja FW, Severson EA, Matheny SL, Brat DJ, Van Meir EG. Hypoxia and the hypoxia-inducible-factor pathway in glioma growth and angiogenesis. *Neuro Oncol*. 2005;7:134-153.
40. Jensen RL, Ragel BT, Whang K, Gillespie D. Inhibition of hypoxia inducible factor-1alpha (HIF-1alpha) decreases vascular endothelial growth factor (VEGF) secretion and tumor growth in malignant gliomas. *J Neurooncol*. 2006;78:233-247.
41. Fukumura D, Kashiwagi S, Jain RK. The role of nitric oxide in tumour progression. *Nat Rev Cancer*. 2006;6:521-534.
42. Fukumura D, Xu L, Chen Y, Gohongi T, Seed B, Jain RK. Hypoxia and acidosis independently up-regulate vascular endothelial growth factor transcription in brain tumors in vivo. *Cancer Res*. 2001;61:6020-6024.
43. Lamszus K, Heese O, Westphal M. Angiogenesis-related growth factors in brain tumors. *Cancer Treat Res*. 2004;117:169-190.
44. Mukhopadhyay D, Tsiokas L, Sukhatme VP. Wild-type p53 and v-Src exert opposing influences on human vascular endothelial growth factor gene expression. *Cancer Res*. 1995;55:6161-6165.
45. Goldman CK, Kim J, Wong WL, King V, Brock T, Gillespie GY. Epidermal growth factor stimulates vascular endothelial growth factor production by human malignant glioma cells: a model of glioblastoma multiforme pathophysiology. *Mol Biol Cell*. 1993;4:121-133.
46. Weissenberger J, Steinbach JP, Malin G, Spada S, Rulicke T, Aguzzi A. Development and malignant progression of astrocytomas in GFAP-v-src transgenic mice. *Oncogene*. 1997;14:2005-2013.
47. Shibuya M, Claesson-Welsh L. Signal transduction by VEGF receptors in regulation of angiogenesis and lymphangiogenesis. *Exp Cell Res*. 2006;312:549-560.
48. Ridgway J, Zhang G, Wu Y, et al. Inhibition of Dll4 signalling inhibits tumour growth by deregulating angiogenesis. *Nature*. 2006;444:1083-1087.
49. Noguera-Troise I, Daly C, Papadopoulos NJ, et al. Blockade of Dll4 inhibits tumour growth by promoting non-productive angiogenesis. *Nature*. 2006;444:1032-1037.
50. Hanahan D. Signaling vascular morphogenesis and maintenance. *Science*. 1997;277:48-50.
51. Oliner J, Min H, Leal J, et al. Suppression of angiogenesis and tumor growth by selective inhibition of angiopoietin-2. *Cancer Cell*. 2004;6:507-516.
52. Folkman J. Angiogenesis: an organizing principle for drug discovery? *Nat Rev Drug Discov*. 2007;6:273-286.
53. Batchelor TT, Sorensen AG, di Tomaso E, et al. AZD2171, a pan-VEGF receptor tyrosine kinase inhibitor, normalizes tumor vasculature and alleviates edema in glioblastoma patients. *Cancer Cell*. 2007;11:83-95.
54. Calabrese C, Poppleton H, Kocak M, et al. A perivascular niche for brain tumor stem cells. *Cancer Cell*. 2007;11:69-82.
55. Bao S, Wu Q, Sathornsumetee S, et al. Stem cell-like glioma cells promote tumor angiogenesis through vascular endothelial growth factor. *Cancer Res*. 2006;66:7843-7848.
56. Stark-Vance V. Bevacizumab (Avastin) and CPT-11 (Camptosar) in the treatment of relapsed malignant glioma. *Neuro Oncol*. 2005;7:369.
57. Norden AD, Young GS, Setayesh K, et al. Bevacizumab for recurrent malignant gliomas: efficacy, toxicity, and patterns of recurrence. *Neurology*. 2008;70:779-787.
58. Guiu S, Taillibert S, Chinot O, et al. [Bevacizumab/irinotecan. An active treatment for recurrent high grade gliomas: preliminary results of an ANOCEF Multicenter Study]. *Rev Neurol (Paris)*. 2008;164:588-594.
59. Pope WB, Lai A, Nghiemphu P, Mischel P, Cloughesy TF. MRI in patients with high-grade gliomas treated with bevacizumab and chemotherapy. *Neurology*. 2006;66:1258-1260.

(Continued on page 768)

(Continued from page 760)

60. Hess C, Vuong V, Hegyi I, et al. Effect of VEGF receptor inhibitor PTK787/ZK222584 [correction of ZK222548] combined with ionizing radiation on endothelial cells and tumour growth. *Br J Cancer*. 2001;85:2010-2016.
61. Wagner SA, Desjardins A, Reardon DA, et al. Update on survival from the original phase II trial of bevacizumab and irinotecan in recurrent malignant gliomas. *J Clin Oncol*. 2008;26(May 20 Suppl):2021.
62. Vredenburgh JJ, Desjardins A, Herndon JE, 2nd, et al. Phase II trial of bevacizumab and irinotecan in recurrent malignant glioma. *Clin Cancer Res*. 2007;13:1253-1259.
63. Vredenburgh JJ, Desjardins A, Herndon JE, 2nd, et al. Bevacizumab plus irinotecan in recurrent glioblastoma multiforme. *J Clin Oncol*. 2007;25:4722-4729.
64. Chen W, Delaloye S, Silverman DH, et al. Predicting treatment response of malignant gliomas to bevacizumab and irinotecan by imaging proliferation with [18F] fluorothymidine positron emission tomography: a pilot study. *J Clin Oncol*. 2007;25:4714-4721.
65. Kreisl TN, Kim L, Moore K, et al. Phase II trial of single-agent bevacizumab followed by bevacizumab plus irinotecan at tumor progression in recurrent glioblastoma. *J Clin Oncol*. 2009;27:740-745.
66. Cloughesy T, Prados MD, Wen PY, et al. A phase II, randomized, non-comparative clinical trial of the effect of bevacizumab (BV) alone or in combination with irinotecan (CPT) on 6-month progression free survival (PFS6) in recurrent, treatment-refractory glioblastoma (GBM). *J Clin Oncol*. 2008;26(May 20 Suppl):2010b.
67. Wachsberger PR, Burd R, Cardi C, et al. VEGF trap in combination with radiotherapy improves tumor control in u87 glioblastoma. *Int J Radiat Oncol Biol Phys*. 2007;67:1526-1537.
68. Holash J, Davis S, Papadopoulos N, et al. VEGF-Trap: a VEGF blocker with potent antitumor effects. *Proc Natl Acad Sci U S A*. 2002;99:11393-11398.
69. De Groot JF, Wen PY, Lamborn K, et al. Phase II single arm trial of aflibercept in patients with recurrent temozolomide-resistant glioblastoma: NABTC 0601. *J Clin Oncol*. 2008;26(May 20 suppl):2020.
70. Batchelor T, Sorensen G, di Tomaso E. A multidisciplinary phase II study of AZD2171 (cediranib), an oral pan-VEGF receptor tyrosine kinase inhibitor, in patients with recurrent glioblastoma. *AAO Meeting Abstracts*. 2008:Abstract LB-247.
71. Goldbrunner RH, Bendszus M, Wood J, Kiderlen M, Sasaki M, Tonn JC. PTK787/ZK222584, an inhibitor of vascular endothelial growth factor receptor tyrosine kinases, decreases glioma growth and vascularization. *Neurosurgery*. 2004;55(2):426-432; discussion 432.
72. Conrad C, Friedman H, Reardon D, et al. A phase I/II trial of single-agent PTK787/ZK 22584 (PTK/ZK), a novel, oral angiogenesis inhibitor, in patients with recurrent glioblastoma (BGM). *J Clin Oncol (ASCO Annual Meeting Abstracts)*. 2004;22:Abst 1512.
73. Kirkpatrick JP, Rich JN, Vredenburgh JJ, et al. Final report: Phase I trial of imatinib mesylate, hydroxyurea, and vatalanib for patients with recurrent malignant glioma (MG). *J Clin Oncol (ASCO Annual Meeting Abstracts)*. 2008;26(May 20 suppl):Abst 2057.
74. Reardon DA, Egorin MJ, Desjardins A, et al. Phase I pharmacokinetic study of the vascular endothelial growth factor receptor tyrosine kinase inhibitor vatalanib (PTK787) plus imatinib and hydroxyurea for malignant glioma. *Cancer*. 2009;115:2188-2198.
75. Liu L, Cao Y, Chen C, et al. Sorafenib blocks the RAF/MEK/ERK pathway, inhibits tumor angiogenesis, and induces tumor cell apoptosis in hepatocellular carcinoma model PLC/PRF/5. *Cancer Res*. 2006;66:11851-11858.
76. Jane EP, Premkumar DR, Pollack IF. Coadministration of sorafenib with rottlerin potentially inhibits cell proliferation and migration in human malignant glioma cells. *J Pharmacol Exp Ther*. 2006;319:1070-1080.
77. Nabors L, Rosenfeld M, Chamberlain M, et al. A phase I trial of sorafenib (BAY 43-9006) for patients with recurrent or progressive malignant glioma (NABTT 0401). *J Clin Oncol (ASCO Annual Meeting Abstracts)*. 2007;25(June 20 Supplement):Abstract 2058.
78. D'Amato RJ, Loughnan MS, Flynn E, Folkman J. Thalidomide is an inhibitor of angiogenesis. *Proc Natl Acad Sci U S A*. 1994;91:4082-4085.
79. Minchinton AI, Fryer KH, Wendt KR, Clow KA, Hayes MM. The effect of thalidomide on experimental tumors and metastases. *Anticancer Drugs*. 1996;7:339-343.
80. Tramontana JM, Utaipat U, Molloy A, et al. Thalidomide treatment reduces tumor necrosis factor alpha production and enhances weight gain in patients with pulmonary tuberculosis. *Mol Med*. 1995;1:384-397.
81. Marx GM, Pavlakis N, McCowatt S, et al. Phase II study of thalidomide in the treatment of recurrent glioblastoma multiforme. *J Neurooncol*. 2001;54:31-38.
82. Puduvalli VK, Giglio P, Groves MD, et al. Phase II trial of irinotecan and thalidomide in adults with recurrent glioblastoma multiforme. *Neuro Oncol*. 2008;10:216-222.
83. Short SC, Traish D, Dowe A, Hines F, Gore M, Brada M. Thalidomide as an anti-angiogenic agent in relapsed gliomas. *J Neurooncol*. 2001;51:41-45.
84. Fine HA, Figg WD, Jaeckle K, et al. Phase II trial of the antiangiogenic agent thalidomide in patients with recurrent high-grade gliomas. *J Clin Oncol*. 2000;18:708-715.
85. Groves MD, Puduvalli VK, Chang SM, et al. A North American brain tumor consortium (NABTC 99-04) phase II trial of temozolomide plus thalidomide for recurrent glioblastoma multiforme. *J Neurooncol*. 2007;81:271-277.
86. Chang SM, Lamborn KR, Malec M, et al. Phase II study of temozolomide and thalidomide with radiation therapy for newly diagnosed glioblastoma multiforme. *Int J Radiat Oncol Biol Phys*. 2004;60:353-357.
87. Kesari S, Schiff D, Henson JW, et al. Phase II study of temozolomide, thalidomide, and celecoxib for newly diagnosed glioblastoma in adults. *Neuro Oncol*. 2008;10:300-308.
88. Fine HA, Wen PY, Maher EA, et al. Phase II trial of thalidomide and carmustine for patients with recurrent high-grade gliomas. *J Clin Oncol*. 2003;21:2299-2304.
89. Drappatz J, Wong ET, Schiff D, et al. A pilot safety study of lenalidomide and radiotherapy for patients with newly diagnosed glioblastoma multiforme. *Int J Radiat Oncol Biol Phys*. 2009;73:222-227.
90. Fine HA, Kim L, Albert PS, et al. A phase I trial of lenalidomide in patients with recurrent primary central nervous system tumors. *Clin Cancer Res*. 2007;13:7101-7106.
91. Knisely JP, Berkey B, Chakravarti A, et al. A phase III study of conventional radiation therapy plus thalidomide versus conventional radiation therapy for multiple brain metastases (RTOG 0118). *Int J Radiat Oncol Biol Phys*. 2008;71:79-86.
92. Vestermark LW, Larsen S, Lindelov B, Bastholt L. A phase II study of thalidomide in patients with brain metastases from malignant melanoma. *Acta Oncol*. 2008;47:1526-1530.
93. Atkins MB, Sosman JA, Agarwala S, et al. Temozolomide, thalidomide, and whole brain radiation therapy for patients with brain metastasis from metastatic melanoma: a phase II Cytokine Working Group study. *Cancer*. 2008;113:2139-2145.
94. Drevs J, Muller-Driver R, Wittig C, et al. PTK787/ZK 222584, a specific vascular endothelial growth factor-receptor tyrosine kinase inhibitor, affects the anatomy of the tumor vascular bed and the functional vascular properties as detected by dynamic enhanced magnetic resonance imaging. *Cancer Res*. 2002;62:4015-4022.
95. Kamoun WS, Ley CD, Farrar CT, et al. Edema Control by cediranib, a vascular endothelial growth factor receptor-targeted kinase inhibitor, prolongs survival despite persistent brain tumor growth in mice. *J Clin Oncol*. 2009;27:2542-2552.
96. Bergers G, Hanahan D. Modes of resistance to anti-angiogenic therapy. *Nat Rev Cancer*. 2008;8:592-603.
97. Hylton N. Dynamic contrast-enhanced magnetic resonance imaging as an imaging biomarker. *J Clin Oncol*. 2006;24:3293-3298.
98. Barrett T, Brechbiel M, Bernardo M, Choyke PL. MRI of tumor angiogenesis. *J Magn Reson Imaging*. 2007;26:235-249.
99. Popperl G, Kreth FW, Herms J, et al. Analysis of 18F-FET PET for grading of recurrent gliomas: is evaluation of uptake kinetics superior to standard methods? *J Nucl Med*. 2006;47:393-403.
100. van den Bent MJ, Vogelbaum MA, Wen PY, Macdonald DR, Chang SM. End point assessment in gliomas: novel treatments limit usefulness of classical Macdonald's Criteria. *J Clin Oncol*. 2009;27:2905-2908.