

Mucormycosis of the Intestine: A Rare Complication in Crohn's Disease

Jordan Morton, MD¹
Vincent Nguyen, MD¹
Tauseef Ali, MD²

¹Department of Internal Medicine, University of Oklahoma Health Sciences Center, Oklahoma City, Oklahoma; ²Department of Internal Medicine, Section of Digestive Diseases and Nutrition, University of Oklahoma Health Sciences Center, Oklahoma City, Oklahoma

Mucormycosis is a rare fungal infection caused by fungi of the order Mucorales, with most cases caused by *Rhizopus* or *Mucor* species. The ubiquitous organisms responsible for infection can be found in decaying vegetation and soil.¹ These rapidly growing fungi produce spores that can easily become airborne. Thus, most individuals have ample exposure to the fungi, with most cases of infection occurring in immunocompromised hosts. Risk factors for infection include diabetes mellitus, diabetic ketoacidosis, neutropenia, corticosteroid use, hematologic malignancies, bone marrow or solid organ transplantation, treatment with deferoxamine, iron overload, AIDS, intravenous drug use, and malnutrition.² Infection can be rhinocerebral, pulmonary, cutaneous, gastrointestinal, renal, or disseminated; gastrointestinal infection comprises only 7% of reported cases.³ This report presents a rare case of gastrointestinal mucormycosis following treatment with corticosteroids in the setting of inflammatory bowel disease.

Case Report

A 38-year-old white female was diagnosed with Crohn's disease in February 2010 when she presented to a local hospital with a 9-month history of abdominal pain and diarrhea. A colonoscopy revealed moderately severe, ulcerative, ileocolonic Crohn's disease. Her primary gastroenterologist placed her on 40 mg oral prednisone and mesalamine (1,600 mg twice daily). She had been smoking 1.5 packs of cigarettes daily for the past

19 years. Her mother also had Crohn's disease. The patient was continued on prednisone at a dose of 40 mg for 2 months, after which she presented to our facility with worsening abdominal pain, hypotension, and sepsis. Her leukocyte count was 28,000/mm³ with 95% neutrophils, and her hemoglobin level was 8.5 g/dL. A computed tomography scan revealed dilated small bowel loops with oral contrast leaking into the peritoneum. An emergency laparotomy was performed, and the patient was found to have a perforated cecum at the level of the ileocecal valve, leading to a temporary cecostomy secondary to dense inflammation and adherent loops of bowel. One week later, she underwent repeat surgery for an end ileostomy with resection of the cecum and terminal ileum. The surgical specimen revealed chronic active inflammation, ulceration, and serositis with fibrinopurulent exudate. Grocott methenamine silver staining was positive for fungal organisms with ribbon-like morphology suggestive of mucormycosis (Figure 1). The glandular structures of the colon demonstrated architectural changes compatible with the patient's history of inflammatory bowel disease. Results of acid-fast bacillus staining were negative. The patient was treated with liposomal amphotericin B at a dose of 500 mg daily for 1 month followed by posaconazole (Noxafil, Schering) at a dose of 400 mg twice daily for 1 month, with gradual improvement in her clinical condition.

Discussion

The pathogenesis of mucormycosis is related to immunocompromised states or immune suppression. With mononuclear and polymorphonuclear phagocytes acting as the main host defense against the Mucorales order,

Address correspondence to:

Dr. Tauseef Ali, Section of Digestive Diseases and Nutrition, University of Oklahoma Health Sciences Center, 1345 WP: 920 SL Young Blvd., Oklahoma City, OK 73104; E-mail: Tauseef-ali@ouhsc.edu

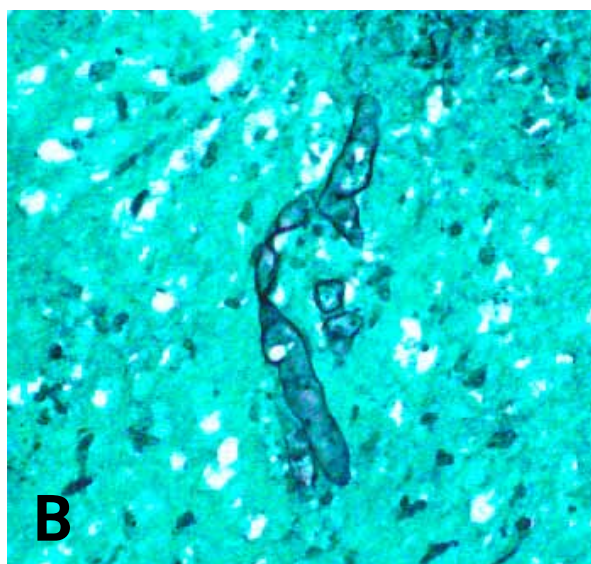
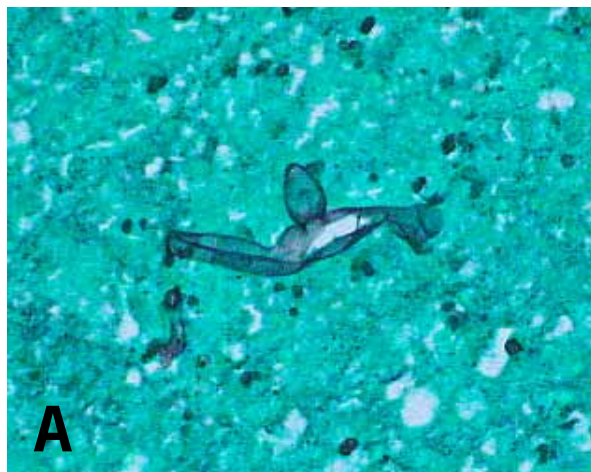


Figure 1. Different views of Grocott methenamine silver stained cecum mucosa showing ribbon-like morphology of the *Mucor* species. Both images are 600 \times magnification.

individuals with hematologic malignancies, neutropenia, corticosteroid use, and/or diabetes are at increased risk for infection.² In patients with diabetic ketoacidosis, the acidic, hyperglycemic environment leads to impaired chemotaxis of neutrophils and interferes with the ability of transferrin to bind iron, a necessary growth factor for fungi.^{1,2} Therefore, mucormycosis is most commonly identified in individuals with impaired host defenses or increased availability of serum iron.

Gastrointestinal mucormycosis is rare and is thought to be secondary to ingestion of fungi.^{2,3} Within the gastrointestinal tract, the stomach is the most common site of infection, followed by the colon, ileum, duodenum, and jejunum.⁴ Symptoms vary by site of infection, with nonspecific abdominal pain, distention, nausea, and vomiting being

the most common symptoms. Due to the high likelihood of bowel perforation, it is of utmost importance to begin empiric treatment with a polyene antifungal drug while diagnostic testing is being performed if clinical suspicion of mucormycosis is high.⁴

Because mucormycosis is generally limited to individuals with underlying defects in host immunity, specifically impaired phagocytic function, patients with Crohn's disease are particularly vulnerable to this infection. This vulnerability is due to both the underlying physiology of Crohn's disease itself, which has been proposed to result from impaired innate immunity, as well as the use of immunosuppressive agents in Crohn's disease treatment, such as corticosteroids and agents that block tumor necrosis factor- α .⁵⁻⁸

Six case reports have described the development of mucormycosis in the setting of inflammatory bowel disease with immunosuppressant therapy (Table 1). One case reported mucormycosis of the sinus in a patient receiving infliximab (Remicade, Janssen Biotech) for ileocecal Crohn's disease.⁹ This patient had been receiving both low-dose azathioprine and infliximab for treatment of Crohn's disease when a sinus biopsy revealed mucormycosis. After administration of amphotericin B and posaconazole and discontinuation of all immunosuppressive agents, laboratory and imaging studies demonstrated clearance of the infection.

Similarly, gastrointestinal mucormycosis presenting as recurrent gastric perforation was reported in a patient with Crohn's disease who was receiving glucocorticoids, 6-mercaptopurine, and infliximab.¹⁰ In this case, because the recurrent perforations were thought to be due to active Crohn's disease, treatment with amphotericin B was delayed, and the patient suffered from multiorgan system failure and subsequent death.

The third case occurred following treatment of pyoderma gangrenosum in the setting of inflammatory bowel disease in a patient who developed a peristomal cutaneous rhizopus infection; this patient was successfully treated with sequential liposomal amphotericin B and itraconazole.¹¹

The fourth case occurred in a patient with Crohn's disease who was being treated with corticosteroids and azathioprine; this patient was admitted due to peritonitis following an intestinal perforation. After initial treatment with voriconazole, resolution of the infection was complicated by recurring peritonitis resulting from necrosis and perforation of the left colon, which ultimately led to death. Microscopic examination of the peritoneal fluid revealed the presence of broad, irregular hyphae, and culture of this fluid yielded *Rhizopus microsporus*.¹²

The fifth case of mucormycosis in a patient with inflammatory bowel disease who was being treated

Table 1. Cases of Mucormycosis in the Setting of Inflammatory Bowel Disease Treated with Immunosuppressants

Study	Age (years)	Sex	Medications	Site(s)	Management	Outcome
Wall GC, Leman BI ⁹	41	Female	Infliximab, azathioprine	Sinus	Amphotericin B, posaconazole, cessation of immunosuppressive agents, debridement of right sinuses	Clearance of infection
Devlin SM, et al ¹⁰	32	Male	75 mg/day 6-mercaptopurine, 5 mg/kg infliximab, high-dose oral/intravenous corticosteroids, broad-spectrum antibiotics	Distal gastric body, gallbladder, liver	Laparotomy with primary closure, cholecystectomy, debridement of liver, amphotericin B, broad-spectrum antibiotics	Multiorgan system failure, recurrent gastrointestinal hemorrhage, death
Hunter AJ, Bryant RE ¹¹	59	Female	Methotrexate, prednisone	Abdominal wall	Liposomal amphotericin B, posaconazole	Clearance of infection
Hyvernat H, et al ¹²	52	Female	Corticosteroids, azathioprine	Peritoneum	Voriconazole	Encapsulated peritonitis, perforated left colon, death
Gubarev N, et al ¹³	37	Male	Corticosteroids, mesalamine	Right atrium, lungs	Amphotericin B	Clinical improvement
Ibañez R, et al ¹⁴	60	Male	Sulfasalazine, methylprednisolone, 6-mercaptopurine	Colon, kidney	Amphotericin B	Multiorgan system failure, death

with immunosuppressant therapy describes a case of mucormycosis endocarditis in an immunocompromised patient with ulcerative colitis whose condition was further complicated by multiple septic emboli to the lungs. The patient was managed with surgical excision of the right atrial endocarditic vegetation and antifungal treatment with high-dose liposomal amphotericin B.¹³

The last case occurred in a 60-year-old male who had recently been diagnosed with inflammatory bowel disease and was treated with total parenteral nutrition, oral sulfasalazine, intravenous methylprednisolone, and oral 6-mercaptopurine. Several weeks later, he developed abdominal pain and bloody diarrhea and subsequently underwent a laparotomy, which found invasion of the colon and kidney by *Absidia corymbifera*. The patient was treated with a low dose of amphotericin B; unfortunately, the case was complicated by multiorgan failure and eventually death.¹⁴

Diagnosis of mucormycosis can be based on either growth of the mold on culture or histopathologic demonstration on biopsy of aseptate, wide, ribbon-like hyphae that branch at right angles.^{1,2} However, due to

the difficulty of growing organisms from tissue culture, biopsy with histologic identification remains the preferred mode of diagnosis.¹

Treatment for mucormycosis consists of both surgical debridement of necrotic material and administration of liposomal or lipid-based formulations of amphotericin B.² Depending on the site of infection, surgical debridement may not be possible or plausible, as in cases of disseminated disease. Adjunctive treatment options such as use of non-siderophore iron chelators, hyperbaric oxygen, or cytokine therapy with either γ interferon or colony-stimulating factor are being investigated, but these methods have not yet proven to be more beneficial than standard treatment with surgery and amphotericin B.^{4,15}

Although the survival rate for patients with mucormycosis is approximately 50%, mortality can be as high as 100% in cases of disseminated disease.² In patients with high clinical suspicion of mucormycosis, therefore, the importance of early diagnosis, correction of underlying risk factors, and treatment cannot be overemphasized.

References

1. Kauffman CA, Malani AN. Zygomycosis: an emerging fungal infection with new options for management. *Curr Infect Dis Rep*. 2007;9:435-440.
2. Spellberg B, Edwards J Jr, Ibrahim A. Novel perspectives on mucormycosis: pathophysiology, presentation, and management. *Clin Microbiol Rev*. 2005;18:556-569.
3. Roden MM, Zaoutis TE, Buchanan WL, et al. Epidemiology and outcome of zygomycosis: a review of 929 reported cases. *Clin Infect Dis*. 2005;41:634-653.
4. Agha FR, Lee HH, Boland CR, Bradley SF. Mucormycoma of the colon: early diagnosis and successful management. *Am J Roentgenol*. 1985;145:739-741.
5. Lawrence IC, Radford-Smith GL, Bampton PA, et al. Serious infections in patients with inflammatory bowel disease receiving anti-tumor-necrosis-factor-alpha therapy: an Australian and New Zealand experience. *J Gastroenterol Hepatol*. 2010;25:1732-1738.
6. D'Haens G, Colombel JF, Hommes DW, et al. Corticosteroids pose an increased risk for serious infection: an interim safety analysis of the ENCORE registry. *Gastroenterology*. 2008;34(suppl):A-140.
7. Korzenik JR. Is Crohn's disease due to defective immunity? *Gut*. 2007;56:2-5.
8. Vavricka SR, Rogler G. New insights into the pathogenesis of Crohn's disease: are they relevant for therapeutic options? *Swiss Med Wkly*. 2009;139:527-534.
9. Wall GC, Leman BI. Mucormycosis in a Crohn's disease patient treated with infliximab. *Digestion*. 2009;80:182-184.
10. Devlin SM, Hu B, Ippoliti A. Mucormycosis presenting as recurrent gastric perforation in a patient with Crohn's disease on glucocorticoid, 6-mercaptopurine, and infliximab therapy. *Dig Dis Sci*. 2007;52:2078-2081.
11. Hunter AJ, Bryant RE. Abdominal wall mucormycosis successfully treated with amphotericin and intrakonazole. *J Infect*. 2002;44:203-204.
12. Hyvernat H, Dunais B, Burel-Vandenbos F, Guidicelli S, Bernardin G, Gari-Toussaint M. Fatal peritonitis caused by *Rhizopus microsporus*. *Med Mycol*. 2010;48:1096-1098.
13. Gubarev N, Separovic J, Gasparovic V, Jelic I. Successful treatment of mucormycosis endocarditis complicated by pulmonary involvement. *Thorac Cardiovasc Surg*. 2007;55:257-258.
14. Ibañez R, Serrano-Heranz R, Sánchez-Zaballos I, Carbonero P, López G. Disseminated mucormycosis due to *Absidia corymbifera* in a patient with inflammatory bowel disease. *Clin Microbiol Infect*. 1997;3:268-270.
15. Boelaert JR, Van Cutsem J, de Locht M, Schneider YJ, Crichton RR. Deferoxamine augments growth and pathogenicity of *Rhizopus*, while hydroxypyridinone chelators have no effect. *Kidney Int*. 1994;45:667-671.

Review

Gastrointestinal Mucormycosis: An Evolving Disease

Brad Spellberg, MD

Division of General Internal Medicine, Los Angeles Biomedical Institute at Harbor-UCLA Medical Center, Torrance, California; David Geffen School of Medicine at UCLA, Los Angeles, California

Mucormycosis is a life-threatening infection caused by fungi of the subphylum Mucoromycotina, order Mucorales.¹ Traditional risk factors for the development of invasive mucormycosis include diabetes, defects in host phagocytes, corticosteroid use, organ or stem cell transplantation, and increased levels of available serum iron as a result of acidosis or administration of deferoxamine.²⁻⁴ In recent years, the disease has also increasingly been described in patients without traditional risk factors.²

Mucormycosis can affect any organ system, but the most common presentations involve either the nasal

sinuses, orbit, and brain (rhino-orbital-cerebral) or the lung. For many years, gastrointestinal mucormycosis was quite rare, especially in industrialized nations. However, there has been a substantial increase in the number of cases of gastric and gastrointestinal mucormycosis indexed on PubMed over the past 2 decades, particularly over the past decade. For example, a PubMed search for the title words "gastric" or "gastrointestinal" and "mucormycosis" or "zygomycosis" revealed 8 publications from 1959–1989 (31 years), 23 publications from 1990–1999 (10 years), and 50 publications from 2000–2011 (12 years).

The stomach is the most common site of gastrointestinal mucormycosis, followed by the colon and ileum. In the past, gastrointestinal mucormycosis was seen primarily in premature neonates, often in association with widespread disseminated disease.⁵⁻¹² For example, necrotizing enterocolitis has been described largely in premature neonates and, more rarely, in neutropenic adults.^{8,9,13-20} Other rare cases of gastrointestinal mucormycosis were previously described in association with other immunocompromising conditions, including AIDS, systemic lupus erythematosus, and organ transplantation.²¹⁻²⁶ Cases of hepatic mucormycosis have also been associated with ingestion of herbal medications.²⁷ Because this infection is acute and rapidly fatal, it is often diagnosed postmortem.

The symptoms of gastrointestinal mucormycosis are varied and depend on the affected site. Nonspecific abdominal pain and distention associated with nausea and vomiting are the most common symptoms. Fever and

Address correspondence to:
Dr. Brad Spellberg, 1124 W. Carson St. RB3, Torrance, CA 90502;
Tel: 310-781-3680; E-mail: bspellberg@labiomed.org

hematochezia may also occur. The patient is often thought to have an intra-abdominal abscess. The diagnosis may be made by biopsy of the suspected area during surgery or endoscopy. Recently, an iatrogenic outbreak of gastric mucormycosis occurred due to contamination of wooden applicators that were used to mix drugs for patients with nasogastric feeding tubes.²⁸ These patients presented with massive gastric bleeds. The diagnosis was made by culturing gastric aspirates and the wooden tongue depressors. This experience further underscores the alarming trend of increasing iatrogenic/nosocomial onset of mucormycosis.

As mentioned previously, older clinical literature (prior to 1990) primarily describes cases of mucormycosis in neonates and premature infants.¹⁵⁻¹⁸ During the 1990s, cases were predominantly described in patients receiving immunosuppressant medications due to solid organ transplantation.^{23,24,29,30} While such cases continue to be described in the 21st century, a substantial proportion of the cases described since 2000 have occurred in more widely disparate patient populations; these patients may have risk factors such as diabetes mellitus or corticosteroid use, a gastric or peptic ulcer that apparently became infected with the fungi, or no predisposing risk factors.^{4,31-37}

The case reported by Morton and colleagues is typical of the increasing experience with this illness in the 21st century.³⁸ This patient had preexisting gastrointestinal mucosal ulcerations due to her underlying Crohn's disease, and she was immunosuppressed due to her corticosteroid therapy. When she presented with her perforation, there was no specific reason to suspect mucormycosis; indeed, the disease was much less likely than more typical causes of colonic perforations in such patients. Only the appearance of the fungi on histopathology caused the diagnosis to be made and appropriate therapy to be initiated. Thus, this case highlights the need to maintain a high index of suspicion for invasive fungal infections, including mucormycosis, in patients who are being treated with corticosteroids and who present with disease that crosses tissue planes.

The need to make a rapid diagnosis is underscored by recent data from the oncology setting, in which initiation of polyene antifungal therapy within 6 days of presentation was strongly associated with improved survival.³⁹ There have been no prospective randomized trials to define the optimal antifungal therapy for mucormycosis. Nevertheless, primary antifungal therapy for mucormycosis should be based on a polyene antifungal agent, as this drug class is by far the most active against the relevant pathogens. Most experts prefer to use lipid formulations of amphotericin B, which can be administered at higher doses and with less toxicity than amphotericin B deoxycholate.³ The role of combination therapy in mucormy-

cosis remains unclear, although data from mouse studies and concordant retrospective data in humans suggest that combining lipid polyenes with echinocandins may improve outcomes.³ Additional research is needed to confirm this hypothesis in prospective trials.

Antifungal therapy alone is typically inadequate to control mucormycosis, and surgery to debulk the fungal infection and/or resect all infected tissue is often required to effect cure. Aside from the resistance of some fungal strains to amphotericin B, several hallmark features of mucormycosis—including angioinvasion, thrombosis, and tissue necrosis—result in poor penetration of anti-infective agents to the site of infection. Therefore, even if the causative organism is susceptible to the antifungal agent *in vitro*, the antifungal agent may be ineffective *in vivo*. In a logistic regression model, surgery was found to be an independent variable for favorable outcomes in patients with mucormycosis.² Furthermore, in multiple case series, patients who did not undergo surgical debridement of mucormycosis had a far higher mortality rate than patients who underwent surgery.⁴⁰⁻⁴⁸ While there is potential selection bias in these case series—patients who did not undergo surgery likely differed in disease severity and/or comorbidities from those who did undergo surgery—these data support the concept that surgical debridement is necessary to optimize cure rates. Finally, immunosuppressive medications, particularly corticosteroids, should be dose-reduced or stopped if at all possible.

Given the increasing incidence of cancer in the aging US population, an ongoing epidemic of obesity and diabetes, and the increasing population of patients receiving corticosteroid therapy for inflammatory diseases and/or solid organ or stem cell transplantation, it is not surprising that recent studies have reported alarming increases in the incidence of mucormycosis.⁴⁹⁻⁵¹ Clinicians will likely continue to encounter this disease more frequently in the coming years, especially in the nosocomial setting. Further research is needed regarding new diagnostic and therapeutic modalities for these devastating infections. In the meantime, improvement in patient outcomes will require a high index of suspicion and emergent diagnostic evaluation to allow early initiation of antifungal and surgical therapy.

References

- Hibbett DS, Binder M, Bischoff JF, et al. A higher-level phylogenetic classification of the Fungi. *Mycol Res*. 2007;111:509-547.
- Roden MM, Zaoutis TE, Buchanan WL, et al. Epidemiology and outcome of zygomycosis: a review of 929 reported cases. *Clin Infect Dis*. 2005;41:634-653.
- Spellberg B, Walsh TJ, Kontoyiannis DP, Edwards J Jr, Ibrahim AS. Recent advances in the management of mucormycosis: from bench to bedside. *Clin Infect Dis*. 2009;48:1743-1751.
- Spellberg B, Edwards J Jr, Ibrahim A. Novel perspectives on mucormycosis: pathophysiology, presentation, and management. *Clin Microbiol Rev*. 2005;18:556-569.
- Gatling RR. Gastric mucormycosis in a newborn infant; a case report. *AMA Arch Pathol*. 1959;67:249-255.

6. Kahn LB. Gastric mucormycosis: report of a case with a review of the literature. *S Afr Med J*. 1963;37:1265-1269.
7. Sharma MC, Gill SS, Kashyap S, et al. Gastrointestinal mucormycosis—an uncommon isolated mucormycosis. *Indian J Gastroenterol*. 1998;17:131-133.
8. Reimund E, Ramos A. Disseminated neonatal gastrointestinal mucormycosis: a case report and review of the literature. *Pediatr Pathol*. 1994;14:385-389.
9. Kecskes S, Reynolds G, Bennett G. Survival after gastrointestinal mucormycosis in a neonate. *J Paediatr Child Health*. 1997;33:356-359.
10. Kline MW. Mucormycosis in children: review of the literature and report of cases. *Pediatr Infect Dis*. 1985;4:672-676.
11. Craig NM, Lueder FL, Pensler JM, et al. Disseminated *Rhizopus* infection in a premature infant. *Pediatr Dermatol*. 1994;11:346-350.
12. Amin SB, Ryan RM, Metlay LA, Watson WJ. *Absidia corymbifera* infections in neonates. *Clin Infect Dis*. 1998;26:990-992.
13. Vadeboncoeur C, Walton JM, Raisen J, Soucy P, Lau H, Rubin S. Gastrointestinal mucormycosis causing an acute abdomen in the immunocompromised pediatric patient—three cases. *J Pediatr Surg*. 1994;29:1248-1249.
14. White CB, Barcia PJ, Bass JW. Neonatal zygomycotic necrotizing cellulitis. *Pediatrics*. 1986;78:100-102.
15. Woodward A, McTigue C, Hogg G, Watkins A, Tan H. Mucormycosis of the neonatal gut: a “new” disease or a variant of necrotizing enterocolitis? *J Pediatr Surg*. 1992;27:737-740.
16. Diven SC, Angel CA, Hawkins HK, Rowen JL, Shattuck KE. Intestinal zygomycosis due to *Absidia corymbifera* mimicking necrotizing enterocolitis in a preterm neonate. *J Perinatol*. 2004;24:794-796.
17. Siu KL, Lee WH. A rare cause of intestinal perforation in an extreme low birth weight infant—gastrointestinal mucormycosis: a case report. *J Perinatol*. 2004;24:319-321.
18. Nissen MD, Jana AK, Cole MJ, Grierson JM, Gilbert GL. Neonatal gastrointestinal mucormycosis mimicking necrotizing enterocolitis. *Acta Paediatr*. 1999;88:1290-1293.
19. Suh IW, Park CS, Lee MS, et al. Hepatic and small bowel mucormycosis after chemotherapy in a patient with acute lymphocytic leukemia. *J Korean Med Sci*. 2000;15:351-354.
20. ter Borg F, Kuijper EJ, van der Lelie H. Fatal mucormycosis presenting as an appendiceal mass with metastatic spread to the liver during chemotherapy-induced granulocytopenia. *Scand J Infect Dis*. 1990;22:499-501.
21. Brullet E, Andreu X, Elias J, Roig J, Cervantes M. Gastric mucormycosis in a patient with acquired immunodeficiency syndrome [letter]. *Gastrointest Endosc*. 1993;39:106-107.
22. Hosseini M, Lee J. Gastrointestinal mucormycosis mimicking ischemic colitis in a patient with systemic lupus erythematosus. *Am J Gastroenterol*. 1998;93:1360-1362.
23. Singh N, Gayowski T, Singh J, Yu VL. Invasive gastrointestinal zygomycosis in a liver transplant recipient: case report and review of zygomycosis in solid-organ transplant recipients. *Clin Infect Dis*. 1995;20:617-620.
24. Martinez EJ, Cancio MR, Sinnott JT 4th, Vincent AL, Brantley SG. Nonfatal gastric mucormycosis in a renal transplant recipient. *South Med J*. 1997;90:341-344.
25. Mazza D, Gugenheim J, Baldini E, Mouiel J. Gastrointestinal mucormycosis and liver transplantation; a case report and review of the literature [letter]. *Transpl Int*. 1999;12:297-298.
26. Knoop C, Antoine M, Vachiéry JL, et al. Gastric perforation due to mucormycosis after heart-lung and heart transplantation. *Transplantation*. 1998;66:932-935.
27. Oliver MR, Van Voorhis WC, Boeckh M, Mattson D, Bowden RA. Hepatic mucormycosis in a bone marrow transplant recipient who ingested naturopathic medicine. *Clin Infect Dis*. 1996;22:521-524.
28. Maravi-Poma E, Rodriguez-Tudela JL, de Jalon JG, et al. Outbreak of gastric mucormycosis associated with the use of wooden tongue depressors in critically ill patients. *Intensive Care Med*. 2004;30:724-728.
29. Winkler S, Susani S, Willinger B, et al. Gastric mucormycosis due to *Rhizopus oryzae* in a renal transplant recipient. *J Clin Microbiol*. 1996;34:2585-2587.
30. Corley DA, Lindeman N, Ostroff JW. Survival with early diagnosis of invasive gastric mucormycosis in a heart transplant patient. *Gastrointest Endosc*. 1997;46:452-454.
31. Garg PK, Gupta N, Gautam V, Hadke NS. Gastric zygomycosis: unusual cause of gastric perforation in an immunocompetent patient. *South Med J*. 2008;101:449-450.
32. Goswami R, Cabrera-Kapetanios Y, Gupta MP, Thakkar S, Bhanot N. Necrotic gastric ulcer in an elderly patient: a rare case of gastric zygomycosis. *South Med J*. 2010;103:387-388.
33. Benjamin S. Primary gastric mucormycosis: role of preexisting ulcerative and erosive lesions. *J Postgrad Med*. 2009;55:73-74.
34. Chhaya V, Gupta S, Arnaout A. Mucormycosis causing giant gastric ulcers. *Endoscopy*. 2011;43 Suppl 2 UCTN:E289-E290.
35. Shiva Prasad BN, Shenoy A, Nataraj KS. Primary gastrointestinal mucormycosis in an immunocompetent person. *J Postgrad Med*. 2008;54:211-213.
36. Al-Rikabi AC, Al-Dohayan AD, Al-Boukai AA. Invasive mucormycosis in benign gastric ulcer. *Saudi Med J*. 2000;21:287-290.
37. Johnson CB, Ahmeti M, Tyroch AH, Zuckerman MJ, Hakim MN. Gastric mucormycosis as a cause of life-threatening upper gastrointestinal bleeding in a trauma patient. *Am Surg*. 2010;76:E76-E77.
38. Morton J, Nguyen V, Ali T. Mucormycosis of the intestine: a rare complication in Crohn's disease. *Gastroenterol Hepatol (N Y)*. 2012;8:137-140.
39. Chamilos G, Lewis RE, Kontoyiannis DP. Delaying amphotericin B-based frontline therapy significantly increases mortality among patients with hematologic malignancy who have zygomycosis. *Clin Infect Dis*. 2008;47:503-509.
40. Nithyanandam S, Jacob MS, Battu RR, Thomas RK, Correa MA, D'Souza O. Rhino-orbital-cerebral mucormycosis. A retrospective analysis of clinical features and treatment outcomes. *Indian J Ophthalmol*. 2003;51:231-236.
41. Peterson KL, Wang M, Canalis RE, Abemayor E. Rhinocerebral mucormycosis: evolution of the disease and treatment options. *Laryngoscope*. 1997;107:855-862.
42. Khor BS, Lee MH, Leu HS, Liu JW. Rhinocerebral mucormycosis in Taiwan. *J Microbiol Immunol Infect*. 2003;36:266-269.
43. Petrikos G, Skiada A, Sambatakou H, et al. Mucormycosis: ten-year experience at a tertiary-care center in Greece. *Eur J Clin Microbiol Infect Dis*. 2003;22:753-756.
44. Tedder M, Spratt JA, Anstadt MP, Hegde SS, Tedder SD, Lowe JE. Pulmonary mucormycosis: results of medical and surgical therapy. *Ann Thorac Surg*. 1994;57:1044-1050.
45. Pavie J, Lafaurie M, Lacroix C, et al. Successful treatment of pulmonary mucormycosis in an allogenic bone-marrow transplant recipient with combined medical and surgical therapy. *Scand J Infect Dis*. 2004;36:767-769.
46. Reid VJ, Solnik DL, Daskalakis T, Sheka KP. Management of bronchovascular mucormycosis in a diabetic: a surgical success. *Ann Thorac Surg*. 2004;78:1449-1451.
47. Asai K, Suzuki K, Takahashi T, Ito Y, Kazui T, Kita Y. Pulmonary resection with chest wall removal and reconstruction for invasive pulmonary mucormycosis during antileukemia chemotherapy. *Jpn J Thorac Cardiovasc Surg*. 2003;51:163-166.
48. Kontoyiannis DP, Wessel VC, Bodey GP, Rolston KV. Zygomycosis in the 1990s in a tertiary-care cancer center. *Clin Infect Dis*. 2000;30:851-856.
49. Kontoyiannis DP, Lionakis MS, Lewis RE, et al. Zygomycosis in a tertiary-care cancer center in the era of *Aspergillus*-active antifungal therapy: a case-control observational study of 27 recent cases. *J Infect Dis*. 2005;191:1350-1360.
50. Marr KA, Carter RA, Crippa F, Wald A, Corey L. Epidemiology and outcome of mould infections in hematopoietic stem cell transplant recipients. *Clin Infect Dis*. 2002;34:909-917.
51. Gleissner B, Schilling A, Anagnostopoulos I, Siehl I, Thiel E. Improved outcome of zygomycosis in patients with hematological diseases? *Leuk Lymphoma*. 2004;45:1351-1360.