

Occult Breast Malignancy Masquerading as Acute Hepatic Failure

Raktima Goswami, MD¹

Michael Babich, MD²

Katie F. Farah, MD²

¹Department of Medicine, ²Division of Gastroenterology,
Allegheny General Hospital, Pittsburgh, Pennsylvania

Although the most commonly identified causes of acute liver failure (ALF) are drug toxicities and viral hepatitis, neoplastic infiltration of the liver can also cause ALF. This case report describes acute hepatic decompensation from an occult breast malignancy that was diagnosed antemortem and discusses 2 previously reported cases of this condition in which the diagnosis was made postmortem.

Case Report

A 38-year-old woman with no significant past medical history presented to our hospital with a 2-week history of malaise, lethargy, sore throat, and dyspnea. A physical examination revealed normal vital signs and mild pharyngeal erythema. The patient's laboratory tests revealed a white blood cell count of 13,500 cells/mm³, with 37% neutrophils, 41% lymphocytes, 8% bands, 2% myelocytes, and 3% metamyelocytes. Her hemoglobin level was 14.4 g/dL, and her platelet count was 123,000 cells/mm³. A peripheral blood smear revealed thrombocytopenia, normal red blood cell morphology, and 4% atypical lymphocytes. Liver function tests (LFTs) revealed a total bilirubin (TB) level of 1.3 mg/dL, alkaline phosphatase (ALP) of 235 IU/L, alanine transaminase (ALT) of 450 IU/L, aspartate aminotransferase (AST) of 491 IU/L, international normalized ratio (INR) of 1.7, and amylase of 104 IU/L. The patient's D-dimer and C-reactive protein levels were increased to 18.16 µg/mL and 34.0 mg/L, respectively. An electrocardiogram and chest radiograph were unremarkable. A computed tomography (CT) scan of the chest, abdomen, and pelvis revealed ground glass opacities and small juxtapleural nodules bilaterally in the lower lobes, a small pericardial and left pleural effusion, a

small amount of perihepatic ascites, and a heterogeneous-appearing liver.

The patient was admitted for possible viral syndrome or atypical bacterial pneumonia. Treatment with empiric moxifloxacin was started. Negative test results were found for Epstein-Barr virus capsid immunoglobulin (Ig)M antibody, cytomegalovirus IgM antibody, Group A *Streptococcus* rapid antigen, nasopharyngeal influenza antigen, *Legionella* urine antigen, *Chlamydia* and *Mycoplasma* serologies, and blood and oropharyngeal cultures. Additionally, negative results were found for antinuclear antibody; antineutrophilic cytoplasmic antibody; anti-double-stranded DNA; acute and chronic hepatitis A, B, and C serologies; antimitochondrial antibody; antismooth muscle antibody; and alpha-1 antitrypsin. A transthoracic echocardiogram was unremarkable.

The patient was treated conservatively and discharged with a presumptive diagnosis of viral syndrome. However, she returned 2 weeks later with complaints of progressive fatigue, abdominal discomfort, and new abdominal distension. Physical examination findings included hepatomegaly and shifting dullness suggestive of ascites. Her LFTs revealed a TB level of 2.2 mg/dL, direct bilirubin of 1.22 mg/dL, ALP of 255 IU/L, AST of 876 IU/L, ALT of 496 IU/L, gamma-glutamyl transpeptidase of 361 IU/L, and INR of 2.1. The patient's lactate dehydrogenase measured 1,138 IU/L, and her complete blood cell count showed a hemoglobin level of 8.6 g/dL and platelet count of 35,000 cells/mm³. Her serum acetaminophen level was undetectable. A repeat CT scan revealed an enlarged heterogeneous liver; periportal adenopathy; an increase in pericardial, pleural, and peritoneal fluids; disseminated lytic vertebral body lesions; left axillary adenopathy; and the development of right-sided hydronephrosis. A transjugular liver biopsy revealed severe acute hepatitis with necrosis, evolving fibrosis, and many monomorphic atypical cells staining positive for CAM 5.2, AE1/3, Her-2/neu (score 3), mammaglobin, GCDFP-15, and CK 7, which are sug-

Address correspondence to:

Dr. Raktima Goswami, Department of Medicine, Allegheny General Hospital,
320 East North Avenue, Pittsburgh, PA 15212; Tel: 412-359-4971;
Fax: 412-359-4983; E-mail: raktimag@gmail.com

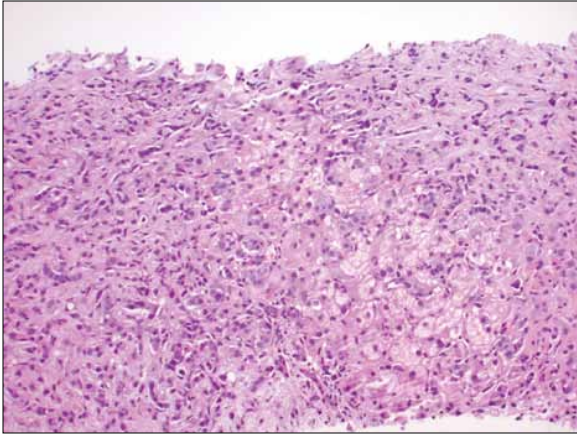


Figure 1. Monomorphic atypical cells seen on histopathology of the liver.

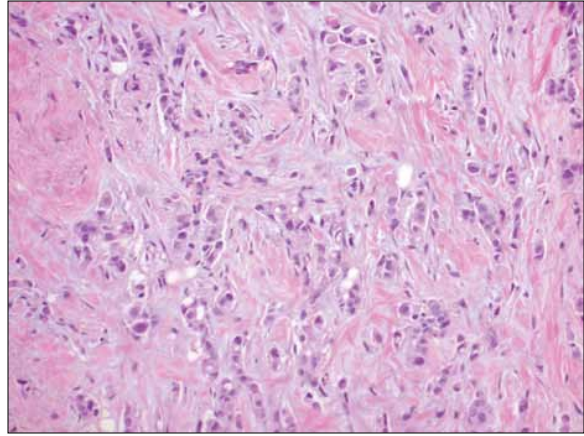


Figure 2. Atypical cells invading the breast stroma.

gestive of primary breast carcinoma metastases (Figure 1). A liver biopsy also revealed elevated indirect portal pressure with an elevated portosystemic gradient of 19 mmHg (normal range, 8–12 mmHg). A mammogram showed a suspicious calcification in the left breast, and an ultrasound of the breast showed a retroareolar mass measuring 1.3 cm × 0.9 cm × 1.1 cm and left axillary adenopathy. A core biopsy of the left retroareolar lesion revealed invasive ductal carcinoma (nuclear grade 2) with lymphovascular invasion (Figure 2). An immunohistochemical stain was negative for estrogen receptor protein, positive for progesterone receptor protein (60%), and positive (3+) for HER-2/neu. Cytologic analysis of ascitic fluid and bone marrow aspirate revealed atypical cells, which is suggestive of metastatic breast carcinoma. A bone marrow biopsy revealed marked fibrosis and pleomorphic neoplastic cells. Tumor cells were positive for CAM 5.2, AE1/3, Her-2/neu (3+), mammaglobin, GCDFP-15, and CK 7, which is consistent with metastatic breast carcinoma.

Systemic chemotherapy with docetaxel, cyclophosphamide, trastuzumab (Herceptin, Genentech), and tamoxifen was initiated. The patient's LFTs normalized, and tumor marker studies, including carcinoembryonic antigen, CA 27-29, and CA 15-3, continued to decrease.

The patient was readmitted 6 months later with a 2-week history of personality changes and confusion. Magnetic resonance imaging of the brain revealed diffuse leptomeningeal enhancement and multiple contrast-enhanced parenchymal nodules consistent with leptomeningeal carcinomatosis. The patient's family opted for hospice care, and she was discharged to home hospice on the fourth hospital day.

Discussion

ALF is characterized by sudden liver dysfunction manifesting as coagulopathy and encephalopathy in an individual without preexisting liver disease who has an illness of less than 26 weeks' duration.¹ ALF is a complex and urgent medical condition that poses diagnostic and treatment challenges.¹ Although the most commonly identified causes of ALF are drug toxicities and viral hepatitis, the cause may remain elusive in as many as 20–40% of cases.^{1–3} Neoplastic infiltration of the liver as a cause of ALF is rare. Rowbotham and associates analyzed 4,020 ALF cases over an 18-year period and attributed only 0.44% of these cases to malignant hepatic infiltration.⁴

Liver metastases from both hematologic and solid organ malignancies have been reported to present as fulminant hepatic failure.⁵ Breast carcinoma has also been implicated.^{5,6} In our patient, acute onset of ascites, rapid and progressive elevation of LFTs, and evidence of coagulopathy drew attention toward a primary hepatic pathology and even possible fulminant hepatic failure; however, there was no evidence of encephalopathy. Moreover, the personality changes that developed were attributed to metastases to the brain. The presentation, however, closely mimicked ALF. To date, occult breast malignancy presenting as fulminant liver failure has been reported only twice in the English-language medical literature.^{7,8} In both instances, the diagnosis was made postmortem (Table 1).

Various mechanisms for hepatocellular damage from neoplastic hepatic infiltration have been proposed. Invasion of hepatic and portal vessels by tumor cells may result in ischemia and infarction.⁵ Tumor cells may exert a pressure effect on hepatocytes and compete for oxygen and

Table 1. Comparison of Occult Breast Cancer Cases That Presented as Acute Hepatic Decompensation

Reference	Patient age (years)	Imaging results	Diagnosis	Outcome
Morrison WL, Pennington CR ⁷	57	USG: ill-defined area	At autopsy	Death in 2 weeks
Myszor MF, Record CO ⁸	34	Isotope scan: focal defect USG: hepatomegaly CT scan: normal	At autopsy	Death in 6 days
The current case report	38	USG: heterogeneous liver CT scan: fatty liver, hepatomegaly, ascites	On biopsy	Death in 6 months

CT=computed tomography; USG=ultrasonography.

nutrients, resulting in liver necrosis. Hemodynamic instability accompanying hepatic dysfunction may decrease effective arterial blood volume and further jeopardize hepatic blood flow.⁵

Although liver metastasis from breast carcinoma has been reported, fulminant hepatic failure from the spread of this tumor is rare and poses a diagnostic challenge.^{9,10} Clinical presentation, radiologic findings, and laboratory results are usually nonspecific, inconclusive, and unrevealing.^{5,10} Diagnosis is more challenging when the primary malignancy is occult. Typical radiologic features of hepatic infiltration from a malignancy are target lesions on ultrasonography and irregular areas of low attenuation on contrast-enhanced CT.¹⁰ As with our patient, imaging may be nonspecific, without any focal abnormality of the liver parenchyma.¹⁰ Hepatomegaly and ascites may be the only radiologic findings, as with any other cause of ALF.¹⁰ LFTs may not rise in concordance with the amount of tumor infiltration, causing the degree of hepatic involvement to be underestimated.⁵ The cause of the discordance between the degree of tumor infiltration and radiologic liver findings has been suggested by findings from autopsy studies. In cases where there has been acute hepatic decompensation, tumor cells have been found to invade diffusely into liver sinusoids. This finding contrasts the intense, but more focal, parenchymal infiltration usually found on pathology in the majority of metastatic tumor invasion cases.¹⁰ Given that hepatic parenchyma is not involved, the liver surface tends to be smooth, with no masses or nodularity, despite a significant degree of tumor invasion.^{6,10} Hence, typical findings such as target lesions are not seen on radiologic imaging.¹⁰

Because clinical presentation and noninvasive investigations may not be diagnostic, liver biopsy is the

definitive procedure of choice. The morphologic and immunophenotypic changes found on the liver biopsy of our patient's occult breast carcinoma guided us toward a definitive diagnosis and resulted in rapid initiation of a specific therapy. Early diagnosis has therapeutic as well as prognostic implications. Most cases of ALF from neoplastic hepatic infiltration have an extremely poor prognosis, with death occurring within several days of clinical presentation. Myszor and Record reviewed 25 cases of ALF from hepatic infiltration secondary to hematologic and solid organ malignancies and reported a 100% mortality rate at a mean period of 7.8 days from the time of hospitalization.⁸ Allison and coworkers reviewed cases of breast carcinoma with diffuse hepatic infiltration and reported a mortality rate of 90%, with death occurring from 3 days to 2 months after presentation.⁶ In contrast to previously reported dismal prognoses, our patient survived for 6 months after diagnosis. We believe that early initiation of targeted therapy lengthened the survival of our patient. This case underscores the need for urgent liver biopsy, particularly if work-up for common causes, such as toxins and viral hepatitis, is negative. A high index of clinical suspicion is necessary to institute etiology-targeted therapy that may prolong survival.

The authors thank Dr. Kun Ru, of Allegheny General Hospital, Pittsburgh, Pennsylvania, for help with pathology slides.

References

- Polson J, Lee WM; American Association for the Study of Liver Disease. AASLD position paper: the management of acute liver failure. *Hepatology*. 2005;41:1179-1197.
- Ostapowicz G, Fontana RJ, Schiødt FV, et al. Results of a prospective study of acute liver failure at 17 tertiary care centers in the United States. *Ann Intern Med*. 2002;137:947-954.

3. Yee H, Lidofsky S. Fulminant hepatic failure. In: Feldman M, Siesenger M, Scharschmidt E, eds. *Gastrointestinal and Liver Disease: Pathophysiology, Diagnosis, Management*. Vol 2. Philadelphia, Pennsylvania; Saunders, 1998:1355-1364.
4. Rowbotham D, Wendon J, Williams R. Acute liver failure secondary to hepatic infiltration: a single centre experience of 18 cases. *Gut*. 1998;42:576-580.
5. Rajvanshi P, Kowdley KV, Hirota WK, Meyers JB, Keeffe EB. Fulminant hepatic failure secondary to neoplastic infiltration of the liver. *J Clin Gastroenterol*. 2005;39:339-343.
6. Allison KH, Fligner CL, Parks WT. Radiographically occult, diffuse intrasinusoidal hepatic metastases from primary breast carcinomas: a clinicopathologic study of 3 autopsy cases. *Arch Pathol Lab Med*. 2004;128:1418-1423.
7. Morrison WL, Pennington CR. Liver metastases from an occult breast carcinoma presenting as acute fulminant hepatic failure. *Br J Clin Pract*. 1984;38:273-274.
8. Myszor MF, Record CO. Primary and secondary malignant disease of the liver and fulminant hepatic failure. *J Clin Gastroenterol*. 1990;12:441-446.
9. Carty NJ, Foggit A, Hamilton CR, Royle GT, Taylor I. Patterns of clinical metastasis in breast cancer: an analysis of 100 patients. *Eur J Surg Oncol*. 1995;21:607-608.
10. Roach H, Whipp E, Virjee J, Callaway MP. A pictorial review of the varied appearance of atypical liver metastasis from carcinoma of the breast. *Br J Radiol*. 2005;78:1098-1103.

Review

Metastatic Breast Cancer Presenting as Acute Liver Failure

Hector E. Nazario, MD

Rita Lepe, MD

James F. Trotter, MD

Division of Transplant Hepatology

Department of Medicine

Baylor University Medical Center

Dallas, Texas

The clinical hallmarks of acute liver failure are coagulopathy (international normalized ratio ≥ 1.5) and hepatic encephalopathy in the absence of cirrhosis or preexisting liver disease that occur less than 26 weeks from symptom onset.¹ The vast majority of acute liver failure cases are related to drug toxicity; of these, acetaminophen is the leading cause of acute liver failure in the United States and Europe. Viral hepatitis, such as hepatitis B, as well as autoimmune liver disease and hypoperfusion or shock are also causes of many cases of acute liver failure.¹ Approximately 20–30% of acute liver failure cases have no identifiable etiology. The growing number of case reports and series describing malignant infiltration of the liver presenting as liver failure support raising the index of suspicion for neoplastic infiltration as a potential cause of cases with an unknown etiology.

Hepatic metastasis is not uncommon and has been identified in 40% of autopsies of adults with malignant tumors.² Most of these patients do not show signs or symp-

toms of liver disease. However, hepatic failure can occur as a result of metastatic disease infiltration to the liver, though this is very rare (accounting for only 0.44% in a large retrospective study).³ These infrequent cases of liver failure have been described most commonly for hematologic malignancies, in particular non-Hodgkin lymphomas, but they can also be associated with solid tumors, including small-cell lung cancer and breast cancer.^{2,4,5}

Breast cancer usually spreads to the bones, lungs, and/or liver.⁶ Approximately 40–50% of women with metastatic breast cancer will have liver metastasis at some point during the course of their disease.⁶ Hepatic metastasis can present at the time of diagnosis; however, particularly for patients diagnosed with invasive breast cancer, the metastatic process can occur several years later, even after treatment. Although most of these breast cancer metastases present as discrete masses or lesions that are easily seen in radiographic studies, they may occasionally manifest as diffuse infiltrating neoplasms that are not identified on radiologic studies.⁶ Other times, this infiltrating tumor has a profound desmoplastic reaction that radiographically resembles cirrhosis. This entity is often called pseudocirrhosis or carcinomatous cirrhosis.⁷

The diffusely infiltrating type of metastasis has been most commonly associated with acute liver failure. Most reported cases of acute liver failure from metastatic breast cancer have occurred in patients with a prior history of known and adequately treated breast cancer. Ductal carcinomas of different degrees of invasiveness are by far the most frequently described. Women affected by this aggressive form of metastatic breast cancer are usually middle-aged, ranging from 35 to 63 years. The majority of patients present with 2–6 weeks of fatigue, nausea, anorexia, jaundice, worsening ascites, and different levels of altered mental status.^{2,7-11} In addition, they have markedly elevated total bilirubin, aminotransferases, lactate dehydrogenase, and alkaline phosphatase levels, as well as thrombocytopenia, coagulopathy, and even disseminated intravascular coagulopathy. In a handful of cases, such as the one described by Goswami and associates,

Address correspondence to:

Dr. Hector E. Nazario, Baylor University Medical Center, Roberts Building, 4th fl, 3500 Gaston Avenue, Dallas, TX 75246; Tel: 214-820-8500; Fax: 214-820-8168; E-mail: Hector.Nazario@BaylorHealth.edu

patients present with significant hepatic dysfunction but no hepatic encephalopathy.¹² Some patients present with portal hypertension, as manifested by esophageal variceal bleeding that requires endoscopic therapy.^{7,8} Furthermore, in several cases in which a transjugular liver biopsy was performed to determine the etiology of the liver failure, an elevated hepatic-portal venous pressure gradient was found.^{7,8,12}

In these cases of acute liver failure precipitated by metastatic breast cancer, the most common histologic finding is diffuse massive intrasinusoidal infiltration of the tumor. Some cases also have extensive fibrous tissue driven by a desmoplastic response.⁷ Necrosis is also commonly seen and is associated with intravascular invasion and thrombus formation affecting tissue perfusion. It has been postulated that replacement of over 80–90% of hepatic parenchyma by the tumor could lead to jaundice and liver failure.² Other types of solid tumors, such as melanoma and gastric, prostate, and small-cell lung cancers, have presented as acute liver failure from tumor infiltration and with similar histologic findings to those described for metastatic breast cancer.^{13–19}

Although the exact mechanisms that lead to this infiltrative pattern of metastatic spread are not clear, Allison and colleagues have proposed an interesting concept involving the adhesion proteins E-cadherin and CD44.⁹ Both of these proteins play an important role in mediating cell-to-cell and cell-to-extracellular-matrix adhesion. The 3 cases of intrasinusoidal metastases that they described did not stain or express these proteins. It is thought that the loss of E-cadherin expression is necessary for metastasis to occur by facilitating cell detachment from the primary tumor. The absence of this molecule could explain single-cell infiltration. On the other hand, CD44 has been found to be overexpressed in different tumors, including breast cancer. Transendothelial migration of tumor cells is increased as a result of upregulated CD44 expression of breast cancer cell lines. This process is enhanced by hepatocyte growth factor. In the absence of CD44, carcinoma cells may not be able to invade across endothelial cells to create large metastatic lesions.⁹ The lack of expression of these molecules could explain why malignant cells do not spread past sinusoids. Tissue hypoxia and injury, as well as oxidative stress, could then lead to a release of cytokines that promotes the development of liver failure in an already compromised hepatic parenchyma.²⁰

Acute liver failure as a result of an infiltrating hepatic malignancy is associated with a rapid and aggressive course of clinical deterioration and a very poor prognosis. These patients are treated with supportive care and intensive medical management, as active malignancy is an absolute contraindication for liver transplantation. The use of chemotherapeutic agents is also frequently limited by mark-

edly elevated bilirubin levels and impaired hepatic function, as well as concomitant infections and multi-organ failure.⁶ Nonetheless, early recognition and diagnosis of the etiology of acute liver failure could impact at least short-term survival in this patient population. Achieving this goal requires prompt biochemical, serologic, and histologic investigation along with medical management in an intensive care unit, preferably by a multidisciplinary team of physicians that includes hepatologists, intensivists, and oncologists.

References

- Polson J, Lee WM; American Association for the Study of Liver Disease. AASLD position paper: the management of acute liver failure. *Hepatology*. 2005;41:1179-1197.
- Bégin LR, Boucher D, Lamoureux E. Diffuse hepatic intravascular carcinomatous embolization resulting in fatal liver failure: a clinicopathologic study of 4 cases. *Pathol Res Pract*. 2001;197:433-440.
- Rowbotham D, Wendon J, Williams R. Acute liver failure secondary to hepatic infiltration: a single centre experience of 18 cases. *Gut*. 1998;42:576-580.
- Morali GA, Rozenmann E, Ashkenazi J, Munter G, Braverman DZ. Acute liver failure as the sole manifestation of relapsing non-Hodgkin's lymphoma. *Eur J Gastroenterol Hepatol*. 2001;13:1241-1243.
- Lettieri CJ, Berg BW. Clinical features of non-Hodgkins lymphoma presenting with acute liver failure: a report of five cases and review of published experience. *Am J Gastroenterol*. 2003;98:1641-1646.
- Diamond JR, Finlayson CA, Borges VF. Hepatic complications of breast cancer. *Lancet Oncol*. 2009;10:615-621.
- Sass DA, Clark K, Grzybicki D, Rabinovitz M, Shaw-Stiffel TA. Diffuse desmoplastic metastatic breast cancer simulating cirrhosis with severe portal hypertension: a case of "pseudocirrhosis". *Dig Dis Sci*. 2007;52:749-752.
- Agarwal K, Jones DE, Burt AD, Hudson M, James OF. Metastatic breast carcinoma presenting as acute liver failure and portal hypertension. *Am J Gastroenterol*. 2002;97:750-751.
- Allison KH, Fligner CL, Parks WT. Radiographically occult, diffuse intrasinusoidal hepatic metastases from primary breast carcinomas: a clinicopathologic study of 3 autopsy cases. *Arch Pathol Lab Med*. 2004;128:1418-1423.
- Myszor MF, Record CO. Primary and secondary malignant disease of the liver and fulminant hepatic failure. *J Clin Gastroenterol*. 1990;12:441-446.
- Lowenthal A, Tur-Kaspa R, Brower RG, Almog Y. Acute liver failure complicating ductal breast carcinoma: two cases and literature review. *Scand J Gastroenterol*. 2003;38:1095-1096.
- Goswami R, Babich M, Farah KF. Occult breast malignancy masquerading as acute hepatic failure. *Gastroenterol Hepatol (N Y)*. 2011;7:62-65.
- Montero JL, Muntané J, de las Heras S, Ortega R, Fraga E, De la Mata M. Acute liver failure caused by diffuse hepatic melanoma infiltration. *J Hepatol*. 2002;37:540-541.
- Te HS, Schiano TD, Kahaleh M, et al. Fulminant hepatic failure secondary to malignant melanoma: case report and review of the literature. *Am J Gastroenterol*. 1999;94:262-266.
- Shakir FA, Madhoun M, Whorton J, Hartly R. Metastatic prostatic carcinoma presenting as fulminant hepatic failure. *South Med J*. 2008;101:1049-1050.
- Athanasakis E, Mouloudi E, Prinianakis G, Kostaki M, Tzardi M, Georgopoulos D. Metastatic liver disease and fulminant hepatic failure: presentation of a case and review of the literature. *Eur J Gastroenterol Hepatol*. 2003;15:1235-1240.
- Sawabe M, Kato Y, Ohashi I, Kitagawa T. Diffuse intrasinusoidal metastasis of gastric carcinoma to the liver leading to fulminant hepatic failure. A case report. *Cancer*. 1990;65:169-173.
- Rajvanshi P, Kowdley KV, Hirota WK, Meyers JB, Keeffe EB. Fulminant hepatic failure secondary to neoplastic infiltration of the liver. *J Clin Gastroenterol*. 2005;39:339-343.
- Gilbert J, Rutledge H, Koch A. Diffuse malignant infiltration of the liver manifesting as a case of acute liver failure. *Nat Clin Pract Gastroenterol Hepatol*. 2008;5:405-408.
- Smedsrod B, Le Coureur D, Ikejima K, et al. Hepatic sinusoidal cells in health and disease: update from the 14th International Symposium. *Liver Int*. 2009;29:490-501.